

# A desiccation compound as a biofilm- and necrosis-removing agent: a case series

**Objective:** A new compound, Debrichem (DEBx Medical BV, the Netherlands), a topical desiccation agent (TDA), is an active gel that contains an acidic species with a potent hygroscopic action. When in contact with microorganisms and necrosis, rapid desiccation and carbonisation of the proteins in these microorganisms, as well as of the extracellular matrix of biofilms and necrosis, occurs. The resulting 'precipitate' rapidly dislodges from the wound bed, resulting in a clean wound which granulates, which is a prerequisite for healing by secondary intention.

**Method:** In a retrospective study, a series of mostly large and hard-to-heal lesions of different aetiologies were treated with a one-time application of the TDA, followed by weekly dressing changes.

**Results:** Of the total of 54 lesions included in this case series, 22 were diagnosed as venous leg ulcers (VLUs), 20 as diabetic foot ulcers (DFUs), nine as post-traumatic, hard-to-heal lesions, two as vascular ulcers and one as an ischaemic ulcer. All of the VLUs, 75% of the DFUs and all of the other lesions reached complete granulation.

**Conclusion:** The use of a TDA may contribute to the consistent, fast and easy removal of both biofilms and necrosis, and hence to wound healing.

**Declaration of interest:** All authors are paid consultants or employees of DEBx Medical BV, Rotterdam, the Netherlands. The clinical study itself was not financially supported. The authors have no other conflicts of interest to declare.

biofilm • debridement • necrosis • topical desiccation agent • wound • wound care • wound dressing • wound healing

Ulcers of the legs and feet are typically of a diabetic, arterial or venous origin, although many more aetiologies can lead to ulceration. Ulcers are a major burden to patients—many of these lesions lead to serious morbidity (and often pain, depending on the type of ulcer), with significantly reduced quality of life.<sup>1,2</sup>

The socioeconomic impact of ulcers is high. As an example, the costs of diabetic foot ulcer (DFU) treatment for US Medicare is between \$9–13 billion USD annually (2019 data),<sup>3</sup> with the highest costs associated with inpatient care, particularly hospital admissions and surgical procedures.<sup>3</sup> Venous leg ulcers (VLUs) are responsible for an average increase of \$6391 per annum per patient for the US Medicare system (2014 data).<sup>4</sup>

The chronicity and frequent recurrence of ulcers are the main reasons for the high cost of care.<sup>5–7</sup> The reason for chronicity, among other factors, is a persistent state of (hyper) inflammation of the ulcer,<sup>8–11</sup> which results in significant disturbance of the wound healing process.<sup>12–14</sup>

Bacteria, and particularly the presence of biofilms, also play a role in chronicity.<sup>15</sup> They contribute to the hyperinflammatory environment<sup>16–22</sup> and have a

negative impact on the wound healing process.<sup>23</sup> In one study, biofilm structures were identified in approximately 80% of samples (biopsies) collected from hard-to-heal skin lesions.<sup>18</sup>

Biofilms have enhanced tolerance to antibiotics and antiseptics, as well as to host defence mechanisms.<sup>16,19,22</sup> Therefore, they are difficult to treat with solely (antibiotic or antiseptic) medication. Similarly, necrosis, containing among other components dead tissues and microorganisms, is known to hamper healing.<sup>24–30</sup>

Consequently, the problem of biofilms and necrosis needs to be addressed as an essential step in getting a wound or ulcer to heal,<sup>31</sup> as is reflected in different treatment modalities and protocols.<sup>25,27</sup> Regular and rigorous debridement is the preferred method of removing biofilm and necrosis.<sup>32</sup>

Diverse methods of debridement can be used and include (hydro)surgical, biological, biosurgical and enzymatic techniques, as well as negative pressure wound therapy (NPWT) and other interventions.<sup>27,33–37</sup> All of these methods come with their own benefits and drawbacks,<sup>24,34–36</sup> such as slow activity (enzymes and autolysis)<sup>38,39</sup> or the requirement of specific expertise at a high cost (surgical excision).<sup>40</sup>

A new compound, a topical desiccation agent (TDA) (Debrichem; DEBx Medical BV, the Netherlands) has been designed to overcome a number of the disadvantages of more traditional debriding agents. The working mechanism is based on the rapid desiccating properties of certain acids. Its efficacy was first described in the treatment of acute periodontal abscesses.<sup>41</sup>

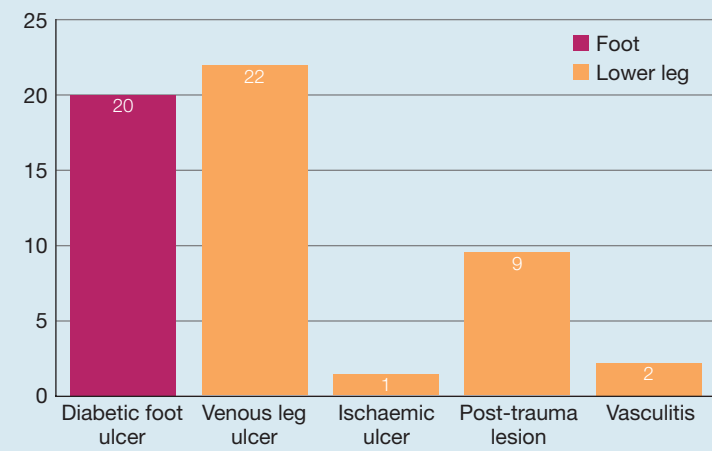
## Trial material and application technique

TDA is an active gel containing an acidic species with a

Alberto Cogo,<sup>1</sup> MD, PhD, Head of the Vascular Medicine Department; A Carlo Bignozzi,<sup>2</sup> Honorary Professor; Michel HE Hermans,<sup>3</sup> MD, President\*; Bert J Quint,<sup>4</sup> MD, PhD, CEO; Johannes Petrus Snels,<sup>4</sup> MSc, Scientific Director; Gregory Schultz,<sup>5</sup> PhD, Professor Emeritus of Obstetrics & Gynecology

\*Corresponding author email: hermans@debix-medical.com

1 Villa Berica Hospital, Vicenza, Italy. 2 Department of Chemical, Pharmaceutical and Agricultural Sciences, University of Ferrara, Ferrara, Italy. 3 Hermans Medical Consulting, the Netherlands. 4 DEBx, Rotterdam, the Netherlands. 5 Department of Obstetrics and Gynecology, Director, Institute for Wound Research. University of Florida, Gainesville, FL, US.

**Fig 1.** Number of lesions per indication and location (n=54)

potent hygroscopic action,<sup>42</sup> which, when in contact with microorganisms and necrosis, leads to swift desiccation and oxidation. This, in turn, causes denaturation of the proteins in bacteria, yeasts and viruses, as well as of the extracellular matrix of biofilms and necrotic tissues. This working mechanism will also harm viable cells and, therefore, TDA should be used within its indications and for a brief period.

Basic cleaning of the wound and the periwound skin is followed by the application of TDA over the lesion and about 1cm of the periwound skin. After 60 seconds, the agent is diluted and removed by rinsing with sterile water or saline. The stratum corneum has a substantially lower water content than the tissues beneath it and, therefore, is not, or is only minimally, affected when exposed to TDA for a short period.

The desiccation effect is virtually immediate; tissues denature, precipitate and coagulate together, and tend to rapidly separate from the underlying surface. There is no specific requirement for dressings or other interventions after application of TDA—these are used at the physician's discretion.

A known side-effect of the application of this type of material is a short-lasting pain sensation during and briefly after the application, which can be prevented by pretreatment of the wound bed with some form of anaesthesia.

The primary goal of using TDA is the rapid elimination of biofilm and necrosis, thus reducing the chance of infection and initiating the 'rebuilding' part of the healing process, by creating a wound bed that can granulate.

## Method

Patients with DFUs, VLU, post-trauma lesions that showed no healing trends, vasculitis ulcers, and an ischaemic ulcer participated in this retrospective study. These diagnoses were established through procedures such as transcutaneous oxygen pressure (TcPO<sub>2</sub>) and ankle-brachial pressure index (ABPI) measurements,

vascular imaging, X-ray evaluation and biopsies. The presence of necrotic tissue and biofilm was established based on the history of the lesions (virtually all lesions of longer duration having a biofilm<sup>18</sup>) as well as on visual inspection.<sup>43,44</sup> For all the ulcers, regular treatment had not resulted in satisfactory healing trends.

Only patients who had received a one-time application of TDA were included in the analysis.

Patients had to be 18 years old or older with a lesion duration of a minimum of four weeks and which was located on the lower leg or foot. If a patient had more than one lesion, only the largest was included in the analysis. There were no other specific inclusion or exclusion criteria. The analysis was approved by the ethical committee of the Villa Berica Hospital in Vicenza (Italy), in line with the Declaration of Helsinki.<sup>45</sup> Patients signed a consent form before participation.

The protocol for the use of TDA, described above, was followed, with the application period being timed at 60 seconds, with subsequent rinsing off.

Follow-up treatment after the application of TDA consisted of Vaseline gauze. This material was chosen to enable the assessment of only the topical effects of the TDA agent, without the results being confounded by 'healing promoting' influences on the wound environment (such as providing a moist interface<sup>46–49</sup>) that more 'active' agents could have delivered. Where possible and appropriate, adjunct therapies, such as offloading and compression, were used after the single treatment with TDA. No additional debridement procedures or techniques were used.

The primary objective of this analysis was to assess the efficacy of TDA after a one-time application. Safety was the secondary objective and was assessed by measuring wound-related detrimental events that could have been attributed to the test product.

Efficacy was measured by visually assessing granulation tissue development (time and percentage): this is an indirect way of evaluating the removal of biofilm and necrosis since the development of granulation tissue is seriously hampered when these detrimental influences are present, while healing by secondary intention requires a granulated wound bed.

Procedural and post-procedural pain were evaluated using a visual analogue scale (VAS), with 0 representing 'no pain' and 5 representing 'very painful'. Both the patient and healthcare provider were asked to compare the treatment to the patient's previous treatment, if possible.

## Demographics

From August 2018 to September 2019 >100 lesions and ulcers of the types described above were treated with TDA. After cleaning up patient records (excluding files because of, for example, too many data points missing, contradictory data points, protocol violations) the files for 54 patients were analysed using Excel (Microsoft Corp., US).

Lesions of 39 (72%) male patients and 15 (28%)

female patients, with an average age of 72.0 years (range: 39–94 years) participated in the trial. Of the lesions, 34 were located on the lower leg and 20 on the foot (Fig 1); 28 (52%) were on the left side of the body and 26 (48%) on the right.

VLUs accounted for 22 (40%) of the lesions, nine (17%) were post-traumatic, hard-to-heal lesions, two (4%) were vascular and one (2%) was an ischaemic ulcer; 20 (37%) lesions were diagnosed as DFUs: two of these were classified as Wagner grade I, six as Wagner II, eight as Wagner III and four as Wagner IV.<sup>50</sup> Because of a shortage of personnel, it was not possible to assess more extensive and specific aetiological aspects of the lesions, particularly to what extent the DFUs were primarily neuropathic or ischaemic in nature.

The mean surface area of all lesions, measured with a ruler, was 57.4cm<sup>2</sup> (range: 2–400cm<sup>2</sup>). For the subgroup of VLUs, the average area was 83.2cm<sup>2</sup> (range: 2–400cm<sup>2</sup>) and for the DFUs it was 43.4cm<sup>2</sup> (range: 3–175cm<sup>2</sup>). For Wagner III and IV ulcers, the volume was measured; the average value was 33.9cm<sup>3</sup> (range: 3–100cm<sup>3</sup>).

The average surface area of the post-traumatic lesions was 15.9cm<sup>2</sup> (range: 2–40cm<sup>2</sup>). The two vasculitis ulcers measured 40cm<sup>2</sup> and 200cm<sup>2</sup>, while the ischaemic ulcer measured 20cm<sup>2</sup> (Fig 2). At the study start, none of the lesions had any granulation tissue coverage.

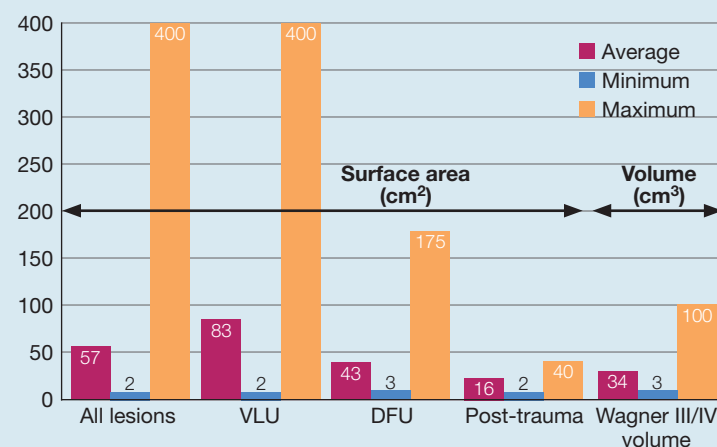
The VLUs had an average duration of 5.3 months (range: 1–12 months), the DFUs 3.7 months (range: 1–12 months) and the post-traumatic lesions 5.6 months (range: 2–12 months). The two vasculitis ulcers and the ischaemic ulcer were each three months old.

All lesions had received different therapies prior to the application of TDA, but since many of these were difficult to determine, only the most recent ones were analysed. These included: iodopovidone gauze (n=24); silver dressing (n=10); moisture retentive dressing (n=8); and collagenase (n=3), with adjunct therapies where indicated (i.e., compression, offloading). A total of nine data points were missing.

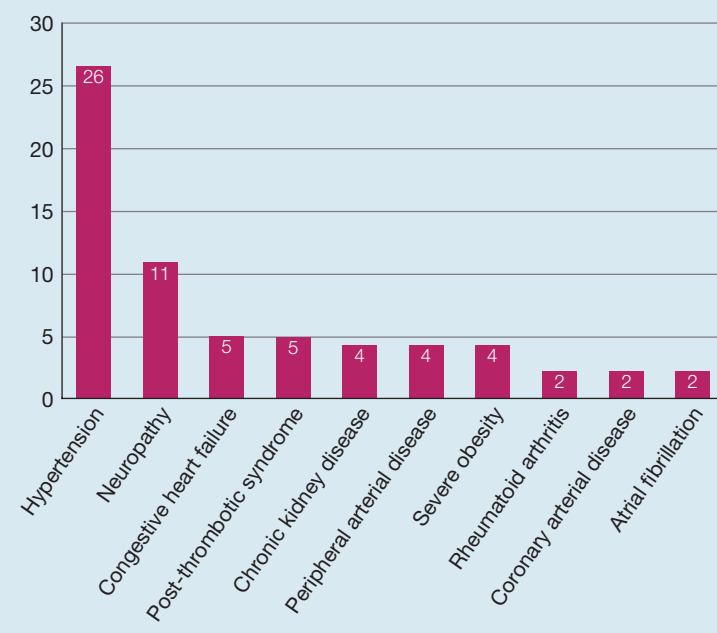
Cumulatively, patients had a total of 73 concomitant diseases (though not all with a known effect on wound healing). Concomitant diseases with a frequency of two or more are listed in Fig 3. Diseases with a frequency of one included: seriously impaired mobility; drug misuse, Cushing disease; paralysis of the limb on which the ulcer was located; dementia; lymphoedema; agenesis of the inferior vena cava; and liver insufficiency. In five cases, medications known to impede wound healing were being used. These were: systemic steroids<sup>51,52</sup> (n=2); methotrexate<sup>53–55</sup> (n=2, both agents); and cyclosporin<sup>53–55</sup> (n=1).

In two patients, osteomyelitis in combination with a Wagner stage III or IV ulcer prior to TDA treatment was present. In these patients, TDA treatment was combined with a toe and forefoot amputation, respectively. A further two patients were shown to have osteomyelitis at a later stage. It was not known whether this complication had been in existence for a prolonged period, particularly when the TDA treatment was applied.

**Fig 2.** Size of lesions. DFU—diabetic foot ulcer; VLU—venous leg ulcer



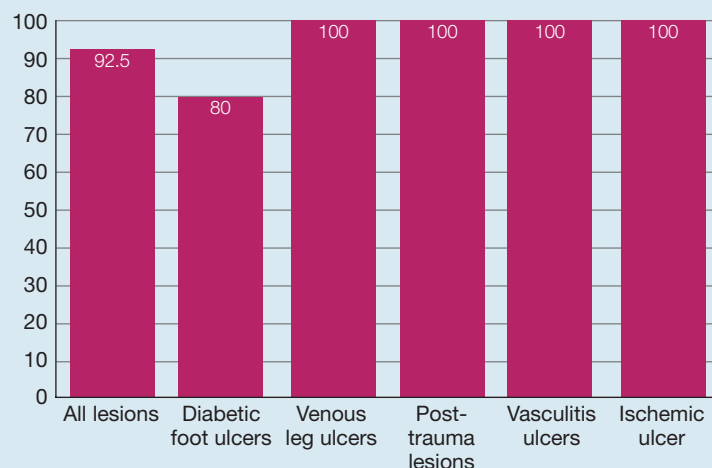
**Fig 3.** Number of concomitant diseases (n≥2)



## Results

With regard to adjunct treatment modalities, 15 (75%) of the 20 patients with DFUs and one (11%) patient of the nine with a post-traumatic lesion used offloading. All patients with VLUs used compression. No antibiotics were administered during the original procedure.

The biofilm and/or necroses generally came away from the underlying tissue within a few days. The exact post-intervention day for this occurrence is not known since patients returned to the clinic seven days later, by which time all lesions were free of clinical signs of biofilm and necrosis.

**Fig 4.** Percentage of total granulation

### Granulation

Complete granulation was achieved by 50 (92.5%) out of 54 lesions in, on average, 36.2 days (range: 2–131 days). All VLU (n=22) reached complete granulation in, on average, 31.6 days (range: 7–95 days). Patients with a DFU achieved complete granulation in 16 (80%) out of 20 cases in, on average, 43.9 days (range: 2–131 days) while the average time to granulation for the post-traumatic lesions (n=9, all lesions) was 34.1 days (range: 7–72 days) (Fig 4).

The two patients with a vasculitis ulcer achieved complete granulation in 12 and 14 days, respectively. The ischaemic ulcer showed complete granulation at day 61.

In four patients, granulation was 0%. The likely reason for this was osteomyelitis (n=2, previously unrecognised in one of these patients) and severe microcirculatory ischaemia (n=2).

Pain was measured using a VAS with 0 representing 'no pain' and 5 representing 'very painful'. Procedural pain (which was expected to occur in some patients) was rated 1.9 on average (range: 0–5) with 15 patients (with diabetes) indicating no pain at all (due to neuropathy). The average level of pain on post-procedural day 1 was rated as 0.2 (range: 0–2) with 48 patients scoring zero. There were no adverse events related to TDA treatment.

Patients and physicians were asked to compare TDA treatment to the patient's most recent previous treatment, even if it was not known what, exactly, that treatment was. For the patients, TDA was considered 'substantially better' by 36/54 (66.6%), 'better' by nine (16.7%), 'similar' by seven (13.0%) and 'worse' by two (3.7%). For the physician, these numbers were 45 (83.3%), five (9.3%), two and two (3.7% each), respectively.

### Discussion

It is difficult to find studies that separately assess the development of granulation. Most studies on methods

and materials in wound care focus on re-epithelialisation as the final outcome, while (the level and speed of) debridement or (the percentage and speed of) granulation tissue development is not specifically assessed. Also, the 'standard' study population for wound care studies, as well as the inclusion and exclusion criteria, are different, and, typically, much more strict than those in our study. As mentioned, our study included relatively large lesions in older patients with medications and/or comorbidities that are known to impede wound healing. In addition, it included patients with Wagner III and IV DFUs. Because of these differences, we decided not to make a comparison to data in the literature.

The principles of using desiccation as an antimicrobial therapy are well established.<sup>56</sup> Experience with chemical injuries (so called 'chemical burns') demonstrates that exposure to acids will cause necrosis.<sup>57–59</sup> In our study, this property is turned into a controlled treatment method to obtain rapid debridement results.

The primary objective of the analyses of this case series was to assess the efficacy of TDA, namely to what extent removal of biofilm and necrosis would lead to complete wound granulation. This is an essential step for successful wound healing to occur<sup>60–64</sup> since these factors interfere negatively with the wound healing process,<sup>22,24–30,65,66</sup> while, for healing by secondary intention, a wound bed covered with granulation tissue is required. The additional objective was to evaluate safety, which was assessed by analysing compound-related adverse events, which did not occur.

To avoid any potential positive influence on the granulation process after the one-time application of TDA, Vaseline gauze was used as the cover dressing for the remainder of the study, although this material is known to be suboptimal for wound healing.<sup>67–70</sup>

The data of 54 patients were used in the analysis, with a limited set of inclusion criteria being applied. With regard to the demographics, this group of patients stands out in a number of ways: compared to most study populations patients were relatively older (average age: 72.0 years) and the size of the lesions was relatively large compared with the ulcers in many publications.<sup>36,39,71,72</sup> Many of the DFUs were classified as Wagner III (n=8) or Wagner IV (n=4) lesions.<sup>50</sup> These types of deep ulcers are typically excluded from wound care trials. The presence of comorbidities and/or the use of medications which have a detrimental influence on healing typically are also exclusion criteria in most trials, but they were not excluded in this research project. Therefore, it is fair to say that, based on these criteria, many of the lesions in this analysis were relatively hard-to-heal, although a run-in period was not used to confirm this clinically. The percentages of granulation per wound type are very high, but the patient and wound properties, as well as the fact that post-TDA application Vaseline gauze was used, may have contributed to the prolonged time before granulation was complete.

The secondary objective of the study was met: there were no TDA-related adverse events and on



post-intervention day 7 all lesions were free of clinical signs of biofilm and necrosis.

### Limitations

The TDA analysis presented here was conducted as a real-life, retrospective analysis of a group of patients with hard-to-heal lesions. Such an analysis has a number of inherent drawbacks—there was a very limited set of inclusion and exclusion criteria, which allowed for different types of lesions to be enrolled, from superficial VLU to Wagner IV DFUs. The fact that there was no specific cut-off time or limitation to the treatment period also makes results difficult to compare with results presented in the literature. In addition, in contrast to most studies, particularly those with DFUs, there was no run-in period to establish that wounds were hard-to-heal, although this is nearly a given for specific lesions such as the deeper and more extensive DFUs and VLUs, and in a patient cohort such as the one used in this study. Also typical for a real-life analysis is that the dataset for all individual patients may not be complete enough to be used in the overall analysis, which was the case in our analysis.

At the same time, the primary purpose of the study, the removal of necrotic material and/or biofilm from hard-to-heal lesions, proved successful, as reflected by the very high percentage of lesions that continued to complete coverage with granulation tissue, the normal initial phase in wound healing once a necrosis- and biofilm-free wound surface has been established.<sup>73–75</sup>

### Conclusion

A retrospective analysis of data on a desiccating agent, used for the removal of biofilm and necrotic material in 54 lesions, was conducted to analyse efficacy and safety of this agent. The lesions included in the analysis were DFUs, VLUs, post-traumatic hard-to-heal lesions, and vasculitic and ischaemic ulcers. The analysis included large and often deep (Wagner III and IV) lesions in patients with a high average age and a number of concomitant diseases.

Results showed a high percentage of granulation tissue formation, the result of successfully creating a proper wound bed without necrosis and biofilm, which is an indication of the efficacy of TDA as a debriding agent. The timeframe in which these results were obtained was relatively long; this is, most likely, due to the fact that, after a one-time application of the TDA compound, wound treatment consisted of only Vaseline gauze, a material known to be suboptimal for wound healing purposes.<sup>67–70</sup>

The results of the study suggest that the use of a TDA may contribute considerably to consistent, fast and easy removal of both biofilm and necrosis.

A prospective and comparative (versus surgical debridement) study on DFUs, VLUs and pressure ulcers is currently being conducted to analyse the results of a one-time TDA application with regard to debridement and the formation of granulation tissue. This study allows for modern materials to be used post-TDA treatment, with a clear end-of-study period. **JWC**

### References

- Pugliese DJ. Infection in venous leg ulcers: considerations for optimal management in the elderly. *Drugs Aging* 2016; 33(2):87–96. <https://doi.org/10.1007/s40266-016-0343-8>
- Situm M, Kolić M, Redzepi G, Antolić S. [Chronic wounds as a public health problem] [article in Croatian]. *Acta Med Croatica* 2014; 68(Suppl 1):5–7
- Geraghty T, LaPorta G. Current health and economic burden of chronic diabetic osteomyelitis. *Expert Rev Pharmacoecon Outcomes Res* 2019; 19(3):279–286. <https://doi.org/10.1080/14737167.2019.1567337>
- Rice JB, Desai U, Cummings AK et al. Burden of venous leg ulcers in the United States. *J Med Econ* 2014; 17(5):347–356. <https://doi.org/10.311/13696998.2014.903258>
- Armstrong DG, Lavery LA, Stern S, Harkless LB. Is prophylactic diabetic foot surgery dangerous? *J Foot Ankle Surg* 1996; 35(6):585–589. [https://doi.org/10.1016/S1067-2516\(96\)80134-7](https://doi.org/10.1016/S1067-2516(96)80134-7)
- Gupta S, Andersen C, Black J et al. Management of chronic wounds: diagnosis, preparation, treatment, and follow-up. *Wounds* 2017; 29(9):S19–S36
- Böhler K. [Venous ulcer] [article in German]. *Wien Med Wochenschr* 2016; 166(9–10):287–292. <https://doi.org/10.1007/s10354-016-0487-5>
- Raffetto JD. Pathophysiology of wound healing and alterations in venous leg ulcers-review. *Phlebology: The Journal of Venous Disease* 2016; 31(1\_suppl Suppl):56–62. <https://doi.org/10.1177/0268355516632998>
- Raffetto JD. Pathophysiology of chronic venous disease and venous ulcers. *Surg Clin North Am* 2018; 98(2):337–347. <https://doi.org/10.1016/j.suc.2017.11.002>
- Tellechea A, Kafanas A, Leal EC et al. Increased skin inflammation and blood vessel density in human and experimental diabetes. *Int J Low Extrem Wounds* 2013; 12(1):4–11. <https://doi.org/10.1177/1534734612474303>
- Zhao R, Liang H, Clarke E et al. Inflammation in chronic wounds. *Int J Mol Sci* 2016; 17(12):2085. <https://doi.org/10.3390/ijms17122085>
- Liu Y, Min D, Bolton T et al. Increased matrix metalloproteinase-9 predicts poor wound healing in diabetic foot ulcers. *Diabetes Care* 2009; 32(1):117–119. <https://doi.org/10.2337/dc08-0763>
- Mannello F, Raffetto JD. Matrix metalloproteinase activity and glycosaminoglycans in chronic venous disease: the linkage among cell biology, pathology and translational research. *Am J Transl Res* 2011; 3(2):149–158
- Pascarella L, Penn A, Schmid-Schönbein GW. Venous hypertension and the inflammatory cascade: major manifestations and trigger mechanisms. *Angiology* 2005; 56(6\_suppl Suppl 1):S3–S10. <https://doi.org/10.1177/00033197050560i102>
- Rajpaul K. Biofilm in wound care. *Br J Community Nurs* 2015; 20(Suppl 3):S6–S11. <https://doi.org/10.12968/bjcn.2015.20.Sup3.S6>
- Bianchi T, Wolcott RD, Peghetti A et al. Recommendations for the management of biofilm: a consensus document. *J Wound Care* 2016; 25(6):305–317. <https://doi.org/10.12968/jowc.2016.25.6.305>
- Loo WT, Sasano H, Chow LW. Pro-inflammatory cytokine, matrix metalloproteinases and TIMP-1 are involved in wound healing after mastectomy in invasive breast cancer patients. *Biomed Pharmacother* 2007; 61(9):548–552. <https://doi.org/10.1016/j.biopha.2007.08.012>
- Malone M, Bjarnsholt T, McBain AJ et al. The prevalence of biofilms in chronic wounds: a systematic review and meta-analysis of published data. *J Wound Care* 2017; 26(1):20–25. <https://doi.org/10.12968/jowc.2017.26.1.20>
- Percival SL, Hill KE, Williams DW et al. A review of the scientific evidence for biofilms in wounds. *Wound Repair Regen* 2012; 20(5):647–657. <https://doi.org/10.1111/j.1524-475X.2012.00836.x>
- Wolcott RD, Rhoads DD, Bennett ME et al. Chronic wounds and the medical biofilm paradigm. *J Wound Care* 2010; 19(2):45–53. <https://doi.org/10.12968/jowc.2010.19.2.46966>
- Wolcott RD, Rhoads DD, Dowd SE. Biofilms and chronic wound inflammation. *J Wound Care* 2008; 17(8):333–341. <https://doi.org/10.12968/jowc.2008.17.8.30796>
- Snyder RJ, Bohn G, Hanft J et al. Wound biofilm: current perspectives and strategies on biofilm disruption and treatments. *Wounds* 2017; 29(6):S1–S17
- Percival SL, Vuotto C, Donelli G, Lipsky BA. Biofilms and wounds: an

identification algorithm and potential treatment options. *Adv Wound Care* 2015; 4(7):389–397. <https://doi.org/10.1089/wound.2014.0574>

**24** Ayello EA, Cuddigan JE. Debridement: controlling the necrotic/cellular burden. *Adv Skin Wound Care* 2004; 17(2):66–75. <https://doi.org/10.1097/00129334-200403000-00012>

**25** Ayello EA, Dowsett C, Schultz GS et al. TIME heals all wounds. *Nursing* 2004; 34(4):36–42. <https://doi.org/10.1097/00152193-200404000-00040>

**26** Gethin G, Cowman S, Kolbach DN. Debridement for venous leg ulcers. *Cochrane Database Syst Rev* 2015; (9):CD008599. <https://doi.org/10.1002/14651858.CD008599.pub2>

**27** Manna B, Nahiriak P, Morrison CA. Wound debridement. StatPearls, Treasure Island (FL), 2019

**28** Mosti G. Wound care in venous ulcers. *Phlebology: The Journal of Venous Disease* 2013; 28(1\_suppl 1):79–85. <https://doi.org/10.1177/0268355513477015>

**29** Turns M. Diabetic foot ulcer management: the podiatrist's perspective. *Br J Community Nurs* 2013; 18(Suppl 2):S14–S19. <https://doi.org/10.12968/bjcn.2013.18.Suppl2.S14>

**30** Whitney J, Phillips L, Aslam R et al. Guidelines for the treatment of pressure ulcers. *Wound Repair Regen* 2006; 14(6):663–679. <https://doi.org/10.1111/j.1524-475X.2006.00175.x>

**31** Percival SL, Suleman L. Slough and biofilm: removal of barriers to wound healing by desloughing. *J Wound Care* 2015; 24(11):498–510. <https://doi.org/10.12968/jowc.2015.24.11.498>

**32** Riley WB Jr. Wound healing. *Am Fam Physician* 1981; 24(5):107–113

**33** Cooper MA, Qazi U, Bass E et al. Medical and surgical treatment of chronic venous ulcers. *Semin Vasc Surg* 2015; 28(3–4):160–164. <https://doi.org/10.1053/j.semvasc.2015.12.003>

**34** Madhok BM, Vowden P, Vowden P. New techniques for wound debridement. *Int Wound J* 2013; 10(3):247–251. <https://doi.org/10.1111/iwj.12045>

**35** Marston W, Tang J, Kirsner RS, Ennis W. Wound healing society 2015 update on guidelines for venous ulcers. *Wound Repair Regen* 2016; 24(1):136–144. <https://doi.org/10.1111/wrr.12394>

**36** Patry J, Blanchette V. Enzymatic debridement with collagenase in wounds and ulcers: a systematic review and meta-analysis. *Int Wound J* 2017; 14(6):1055–1065. <https://doi.org/10.1111/iwj.12760>

**37** Raposio E, Bortolotti S, Maistrello L, Grasso DA. Larval therapy for chronic cutaneous ulcers: historical review and future perspectives. *Wounds* 2017; 29(12):367–373

**38** Bolton L, Corbett L, Bernato L et al.; Government and Regulatory Task Force, Association for the Advancement of Wound Care. Development of a content-validated venous ulcer guideline. *Ostomy Wound Manage* 2006; 52(11):32–48

**39** Mancini S, Cuomo R, Poggialini M et al. Autolytic debridement and management of bacterial load with an occlusive hydroactive dressing impregnated with polyhexamethylene biguanide. *Acta Biomed* 2018; 88(4):409–413. <https://doi.org/10.23750/abm.v88i4.5802>

**40** Gordon KA, Lebrun EA, Tomic-Canic M, Kirsner RS. The role of surgical debridement in healing of diabetic foot ulcers. *Skinmed* 2012; 10(1):24–26

**41** Pini-Prato G, Magnani C, Rotundo R. Treatment of acute periodontal abscesses using the biofilm decontamination approach: a case report study. *Int J Periodontics Restorative Dent* 2016; 36(1):55–63. <https://doi.org/10.11607/prd.2557>

**42** Bignozzi AC, Cogo A, Carinci F. Compositions for removing necrotic or infected tissues from body lesions and from oral cavity. Patent Cooperation Treaty Nr PCT/IB2019/051146 2020; Patent Pending

**43** Metcalf D, Bowler PG. Perceptions of wound biofilm by wound care clinicians. *Wounds* 2019; 31(3):E14–E17

**44** Metcalf DG, Bowler PG, Hurlow J. A clinical algorithm for wound biofilm identification. *J Wound Care* 2014; 23(3):137–142. <https://doi.org/10.12968/jowc.2014.23.3.137>

**45** World Medical Association. WMA Declaration of Helsinki – Ethical Principles for Medical Research Involving Human Subjects: 64th WMA General Assembly; 2013. <https://tinyurl.com/4uvsx7ts> (accessed November 2020)

**46** Beam JW. Occlusive dressings and the healing of standardized abrasions. *J Athl Train* 2008; 43(6):600–607. <https://doi.org/10.4085/1062-6050-43.6.600>

**47** Bruno W, Kerstein MD. Moist wound healing: current concepts and applications. *Surg Technol Int* 1994; 3:37–43

**48** Bryan J. Moist wound healing: a concept that changed our practice. *J Wound Care* 2004; 13(6):227–228. <https://doi.org/10.12968/jowc.2004.13.6.26625>

**49** Chang H, Wind S, Kerstein MD. Moist wound healing. *Dermatol Nurs* 1996; 8(3):174–176

**50** Wagner FW Jr. The dysvascular foot: a system for diagnosis and treatment. *Foot Ankle* 1981; 2(2):64–122. <https://doi.org/10.1177/107110078100200202>

**51** Anstead GM. Steroids, retinoids, and wound healing. *Adv Wound Care* 1998; 11(6):277–285

## Reflective questions

- Why should necrosis and biofilm be removed from a lesion?
- The use of a topical desiccation agent (TDA) contributes to an essential step in certain types of wound healing. What step and what type of wound healing?
- Why are biofilms so difficult to remove?

**52** Goforth P, Gudas CJ. Effects of steroids on wound healing: a review of the literature. *J Foot Surg* 1980; 19(1):22–28

**53** Damert HG, Lenz-Scharf O, Altmann S, Schneider W. [Soft-tissue defects on the dorsum of the hand by extravasation of the cytostatic agents: surgical options of treatment] [article in German]. *Handchir Mikrochir Plast Chir* 2007; 39(6):409–413. <https://doi.org/10.1055/s-2007-965231>

**54** Karrer K, Wurnig P. [Do cytostatics interrupt wound healing] [article in German]. *Klin Med Osterr Z Wiss Prakt Med* 1958; 13(5):196–200

**55** Tala P, Kerminen T. Cytostatics and wound healing: an experimental study with rabbits. *Ann Chir Gynaecol Fenn* 1963; 52:301–306

**56** Schwarzer S, Radzieta M, Jensen SO, Malone M. Efficacy of a topical wound agent methanesulfonic acid and dimethylsulfoxide on in vitro biofilms. *Int J Mol Sci* 2021; 22(17):9471. <https://doi.org/10.3390/ijms22179471>

**57** Mozingo DW, Smith AA, McManus WF et al. Chemical burns. *J Trauma Inj Infect Crit Care* 1988; 28(5):642–647. <https://doi.org/10.1097/00005373-198805000-00014>

**58** Saada V, Patarin M, Sans S, Saiag P. [Cutaneous necrosis caused by hydrofluoric acid] [article in French]. *Ann Dermatol Venerol* 1995; 122(8):512–513

**59** Schwerin DL, Hatcher JD. Hydrofluoric acid burns. StatPearls, Treasure Island (FL), 2022

**60** Franz MG, Robson MC, Steed DL et al.; Wound Healing Society. Guidelines to aid healing of acute wounds by decreasing impediments of healing. *Wound Repair Regen* 2008; 16(6):723–748. <https://doi.org/10.1111/j.1524-475X.2008.00427.x>

**61** Franz MG, Steed DL, Robson MC. Optimizing healing of the acute wound by minimizing complications. *Curr Probl Surg* 2007; 44(11):691–763. <https://doi.org/10.1067/j.cpsurg.2007.07.001>

**62** Steed DL, Attinger C, Colaizzi T et al. Guidelines for the treatment of diabetic ulcers. *Wound Repair Regen* 2006; 14(6):680–692. <https://doi.org/10.1111/j.1524-475X.2006.00176.x>

**63** Leaper DJ, Schultz G, Carville K et al. Extending the TIME concept: what have we learned in the past 10 years? *Int Wound J* 2012; 9(Suppl 2):1–19. <https://doi.org/10.1111/j.1742-481X.2012.01097.x>

**64** Schultz GS, Barillo DJ, Mozingo DW, Chin GA; Wound Bed Advisory Board Members. Wound bed preparation and a brief history of TIME. *Int Wound J* 2004; 1(1):19–32. <https://doi.org/10.1111/j.1742-481X.2004.00008.x>

**65** Hermans MH. An introduction to burn care. *Adv Skin Wound Care* 2019; 32(1):9–18. <https://doi.org/10.1097/01.ASW.0000549612.44844.75>

**66** Percival SL, McCarty SM, Lipsky B. Biofilms and wounds: an overview of the evidence. *Adv Wound Care* 2015; 4(7):373–381. <https://doi.org/10.1089/wound.2014.0557>

**67** Ahmadi H, Durrant C, Williams G. Permanent scarring in a scald burn dressed with paraffin gauze. *J Wound Care* 2009; 18(6):256–258. <https://doi.org/10.12968/jowc.2009.18.6.42805>

**68** Alsbjörn BF, Ovesen H, Walther-Larsen S. Occlusive dressing versus petroleum gauze on drainage wounds. *Acta Chir Scand* 1990; 156(3):211–213

**69** Cuomo R, Grimaldi L, Brandi C et al. Skin graft donor site: a procedure for a faster healing. *Acta Biomed* 2017; 88(3):310–314. <https://doi.org/10.23750/abm.v88i3.5736>

**70** Rippon M, Davies P, White R. Taking the trauma out of wound care: the importance of undisturbed healing. *J Wound Care* 2012; 21(8):359–368. <https://doi.org/10.12968/jowc.2012.21.8.359>

**71** Hansson C; Cadexomer Iodine Study Group. The effects of cadexomer iodine paste in the treatment of venous leg ulcers compared with hydrocolloid dressing and paraffin gauze dressing. *Int J Dermatol* 1998; 37(5):390–396. <https://doi.org/10.1046/j.1365-4362.1998.00415.x>

**72** Lazareth I, Ourabah Z, Senet P et al. Evaluation of a new silver foam dressing in patients with critically colonised venous leg ulcers. *J Wound Care* 2007; 16(3):129–132. <https://doi.org/10.12968/jowc.2007.16.3.27015>

**73** Broughton G 2nd, Janis JE, Attinger CE. Wound healing: an overview. *Plast Reconstr Surg* 2006; 117(7 Suppl):1e–S–32e–S. <https://doi.org/10.1097/01.prs.0000222562.60260.f9>

**74** Childs DR, Murthy AS. Overview of wound healing and management. *Surg Clin North Am* 2017; 97(1):189–207. <https://doi.org/10.1016/j.suc.2016.08.013>

**75** Velnar T, Bailey T, Smrkolj V. The wound healing process: an overview of the cellular and molecular mechanisms. *J Int Med Res* 2009; 37(5):1528–1542. <https://doi.org/10.1177/147323000903700531>