

a new option
for chemical
debridement
using Debrichem to remove
biofilm in hard-to-heal wounds

Contents

- S3 Tackling hard-to-heal wounds with a new option for chemical debridement**
Karen Staines
- S4 Comparing methods of debridement for removing biofilm in hard-to-heal wounds**
Karen Ousey and Liz Ovens
- S11 Introducing a desiccant debridement agent: as effective as a blade, as easy as a pad**
Michel Hermans
- S13 Case study 1. Right venous leg ulceration treated with Debrichem**
Priti Bhatt
- S15 Case study 2. Bilateral venous leg ulceration treated with Debrichem**
Priti Bhatt
- S19 Case study 3. Bilateral venous leg ulceration treated with Debrichem**
Priti Bhatt
- S22 Case study 4. Venous leg ulcers on the left ankle treated with Debrichem**
Priti Bhatt
- S25 Case study 5. Three venous leg ulcers on the right leg treated with Debrichem**
Emma Bennett, Sarah Molden and Katie Leek
- S27 Case study 6. Venous leg ulcer with atrophie blanche treated with Debrichem**
Hayley Turner-Dobbin
- S29 Case study 7. Mixed-aetiology leg ulcer treated with Debrichem**
Annabelle Mooney

MA Healthcare

Published by MA Healthcare Ltd

St Jude's Church, Dulwich Road, London, SE24 0PB, UK
+44 (0)20 7738 6726

www.markallengroup.com

Project editor: Benjamin Wakefield

Project manager: Angela Shaw

Associate publisher: Tracy Cowan

Head of projects: Camila Fronzo

Design: Fonthill Creative

Managing director: Anthony Kerr

anthony.kerr@markallengroup.com

Produced by Mark Allen Medical Communications
with support from DEBx Medical BV

www.mamedcomms.com

© MA Healthcare Ltd 2023

All rights reserved. No reproduction, transmission or copying of this publication is allowed without written permission. No part of this publication may be reproduced, stored in a retrieval system, or transmitted in any form or by any means, mechanical, electronic, photocopying, recording, or otherwise, without the prior written permission of MA Healthcare or in accordance with the relevant copyright legislation.

Although the editor, MA Healthcare Ltd and DebX Medical BV have taken great care to ensure accuracy, neither MA Healthcare Ltd nor DebX Medical BV will be liable for any errors of omission or inaccuracies in this publication.

Declarations of interest: Karen Staines is an employee of Accelerate. Michel Hermans is on the Advisory Board of DEBx Medical. All other authors are independent clinicians who received a fee for their contributions and have no other interests to declare.

Tackling hard-to-heal wounds with a new option for chemical debridement

Karen Staines

Wounds can fail to heal for a variety of reasons. Some of these factors, such as comorbidities and age, are intrinsic, and wound-care services can have little influence on them. However, there are also extrinsic factors, where clinicians can make a positive difference. A key example is wound bed preparation, including debridement.

This supplement begins with a clinical review of wound debridement—the removal of devitalised tissue, such as slough and necrotic tissue, from the wound bed and surrounding area. Debridement can help the clinician to visualise the wound bed, identify if there is any depth to it and, thus, make an accurate clinical assessment. It also encourages angiogenesis, which supports granulation and proliferation of the wound bed. Perhaps most importantly, successful debridement disrupts the biofilm cycle and reduces the risk of infection, which are major causes of delayed healing in hard-to-heal wounds, consequently causing financial burden and reduction in patient quality of life. Debridement can be achieved with a variety of methods, each with advantages and disadvantages in terms of efficacy, cost and ease of use.

The supplement presents a case series on an innovative method of chemical debridement using the debridement gel Debrichem (DEBx Medical BV, Amsterdam, Netherlands). Unlike many other debridement methods, Debrichem can be used by any healthcare professional with minimal training in the patient's home or clinical setting. The solution is applied directly onto the wound bed, left in place for up to 60 seconds and then washed away with saline or sterile water, after which the wound is appropriately dressed. A change in the wound bed's appearance should be visible immediately after application. However, it can take longer for the body to adapt and restart the healing process, resulting in the gradual removal of devitalised tissue and increase in granulation tissue in the wound bed. Therefore, the clinician and patient should set realistic expectations about these

positive changes. To ascertain the effectiveness of the procedure, the wound should be reviewed starting at the first dressing change after application and regularly over the following weeks.

The case series covers patients with a variety of hard-to-heal wounds that had failed to respond to local standardised wound management and appeared static before instigation of Debrichem. Early indications show that Debrichem is an alternative debridement modality able to remove devitalised tissue and the bacterial burden associated with infection and biofilm formation.

The case series includes patients who, before application of Debrichem, received local anaesthetic with 5% lidocaine and prilocaine topically to their wound bed, as well as those who did not. Those who did not have an anaesthetic reported pain up to 10/10, but this rapidly reduced after the solution was thoroughly irrigated off the wound bed. However, patients who received the anaesthetic reported little or no pain, which enabled the solution to be left on for the optimal amount of time for efficacy of treatment.

It may be beneficial to study the efficacy of topical anaesthetic with 5% lidocaine and prilocaine in other methods of debridement where discomfort or pain are common (unless the patient has neuropathy in their wound). These include sharp and mechanical debridement, which physically remove devitalised tissue and are generally considered the gold-standard treatments.

Specialist nurses should aim to select the debridement method for each patient that offers maximum efficacy without any additional discomfort. This may mean being open-minded about new treatment modalities and being willing to explore innovative technology that could change practice and improve rates of healing.

Note: Throughout this supplement, 'wound' is used as an umbrella term, inclusive of the more specific category of 'ulcer' (wounds with primarily intrinsic factors, as opposed to acute wounds with primarily extrinsic factors).

Comparing methods of debridement for removing biofilm in hard-to-heal wounds

Karen Ousey and Liz Ovens

Introduction

All open wounds become contaminated by microorganisms, which can rapidly progress to colonisation.¹ This contamination process may include the formation of biofilm, which can form on the wound surface within 24–48 hours and, when established, increases the risk of delayed healing, infection and sepsis.^{2,3} Biofilm is a major factor in wounds failing to heal in a timely fashion, and it can be found in the vast majority of hard-to-heal wounds.⁴

Consequently, effective wound care involves the disruption and removal of biofilm to initiate and support healing.³ One vital part of an antibiofilm strategy is debridement, the removal of tissue that is infected, damaged or dead (necrosis). This can be achieved with a variety of methods, each with its advantages and disadvantages. Options include autolytic debridement with hydrogel and hydrocolloid wound dressings, which are widely used but may not be effective at removing biofilm,⁵ as well as a range of active debridement techniques (for example, surgical, sharp, mechanical and enzymatic) that are more effective against biofilm.⁶

This article explores the risk factors associated with biofilm development and reformation, the impact this has on wound healing and the various debridement techniques available for clinicians to address this.

The burden of hard-to-heal wounds

Hard-to-heal wounds are wounds that fail to heal with standard therapy in an orderly and timely manner.⁷ This term—synonymous with chronic, non-healing or recalcitrant wounds or failure to heal—can describe wounds of any type or aetiology, whether acute or chronic, that fail to heal within the normal healing trajectory.

Hard-to-heal wounds present a major challenge for health professionals, with the potential for poor patient health and quality-of-life outcomes and substantial costs to healthcare systems.^{8–10}

A meta analysis¹¹ of 11 papers put the global prevalence of hard-to-heal wounds per 1000 population at 1.67 (confidence intervals (CI): 0.83–2.80), although this was 1.51 in reports on leg ulcers alone and 2.21 in reports

covering various aetiologies. The limited number of studies and heterogeneity in study design and data collection means that the data should be considered with caution.¹²

Managing hard-to-heal wounds is expensive. According to a cohort study of the approximately 3.8 million patients with a wound managed by the NHS in 2017/18, £5.6 billion of the NHS's £8.3 billion annual wound management cost was associated with unhealed wounds, compared with £2.7 billion for healed wounds.¹³ Healing rates were lower in those with (45%) than without (59%) evidence of infection in hard-to-heal wounds, although this did not affect healing rates in acute wounds.¹³ Healing rates affected the average 12-month management cost of surgical wounds, which were £6000 in healed and £13700 in unhealed wounds.¹⁴ This average cost was also linked to evidence of infection, which was £2000 in its absence and £5000–£11200 in its presumed presence.¹⁴ An earlier report from the same study series looked at the mean 12-month cost of pressure ulcers in the NHS. This was only £1400 for ulcers of the lowest severity (category 1), compared with >£8500 for ulcers of all other categories, and it was £12300 for unhealed ulcers, 2.4 times more than the £5140 for healed ulcers.¹⁵

Controlling the ever-increasing costs of hard-to-heal wounds will require more resources, better education and greater continuity of care. Cost-effective healing can also be facilitated with earlier and faster wound bed preparation, assisted by the availability of appropriate debridement techniques to a wider range of clinicians.

Risk factors and assessment of hard-to-heal wounds

The chance of delayed wound healing is increased by a number of risk factors (*Box 1*).⁸ These can be related to the wound itself, to any comorbidities or ongoing treatments or to the patient's demographic profile.⁸ Some comorbid conditions often present with a variety of risk factors for hard-to-heal wounds, such as chronic kidney disease, which often involves hypertension, diabetes mellitus, vascular disease, obesity, malnutrition and chronic inflammatory states.¹⁶ Identifying and addressing these

Karen Ousey, Professor and Director of the Institute of Skin Integrity and Infection Prevention, University of Huddersfield

Liz Ovens, Independent Tissue Viability Specialist Nurse

risk factors is essential to promoting and maintaining effective wound healing.

To identify these risk factors, health professionals should conduct a thorough assessment of the patient and their wound. This should include an in-depth assessment of the wound itself, which may involve measuring its depth, location and size, as well as wound culture or biopsy to identify infection and bioburden. Understanding the underlying aetiology and pathophysiology can help identify what caused the wound in the first place or may be presenting significant barriers to healing. For example, this could reveal an endogenous tissue-breakdown mechanism that is preventing the wound from following the normal healing trajectory, which is associated with tissue-destructive enzymes (principally matrix metalloproteinases), an oxidative environment (caused by reactive oxygen

species) or impaired endogenous control mechanisms (which modulate enzyme activities).

Likewise, measuring biochemical parameters, such as blood glucose, renal function and inflammatory markers, can help identify relevant comorbidities so that they can be managed.¹⁷ This clinical assessment should be accompanied by a holistic assessment of the patient's medical history, covering any known comorbidities and ongoing treatments, as well as any relevant personal demographic, social and psychological information. The results of this in-depth, holistic assessment can then be used to guide the selection of interventions that optimise healing outcomes in hard-to-heal wounds.⁸

Initial assessment should be followed by a consistent cycle of reassessment to monitor outcomes. This is essential to determine the response to any interventions and enable any appropriate and timely changes to the treatment plan.¹⁸

Box 1. Risk factors for hard-to-heal wounds

Wound-related	<ul style="list-style-type: none"> × Aetiology × Bioburden × Depth × Duration × Location × Pathophysiology × Size
Comorbidity-related	<ul style="list-style-type: none"> × Anaemia × Cancer × Chronic inflammation × Diabetes mellitus × Hypertension × Hypoxia × Immobilisation × Immune disease × Lymphatic insufficiency × Neuropathy × Oedema (if on lower limbs) × Vascular (arterial or venous) disease
Treatment-related	<ul style="list-style-type: none"> × Adherence × Immune suppression × Radiation × Systemic medication
Patient-related	<ul style="list-style-type: none"> × Behaviour × Demographics × Genetics × Malnutrition × Obesity × Older age × Psychological wellbeing × Smoking × Socioeconomic status

Biofilm and hard-to-heal wounds

One of the most significant risk factors for hard-to-heal wounds is bioburden, including the presence of biofilm. Biofilm refers to a collection of microorganisms that have formed an extracellular polysaccharide substance, a protective environment that makes them difficult to eradicate with antimicrobial agents.¹⁹ These complex colonies of microorganisms can be diverse, including bacteria, proteins and DNA, and they can survive attached to a living or non-living surface.²⁰

Biofilms typically cause and maintain ongoing inflammation and low-level infection, and they have been shown to have a negative impact on wound healing.^{20,21} Wound biofilm increases risk of infection, and this risk can be multiplied where there are increased microbial virulence, antibiotic/antimicrobial resistance or impaired host defences, such as in diabetes and obesity.²² Bacteria that form biofilm are sessile (fixed in place) as opposed to planktonic (freely moving). However, the biofilm cycle has been shown to involve the release of planktonic bacteria, which can cause acute infection and increase the risk of wound chronicity.²¹ According to an in vitro analysis of the efficacy of antimicrobial agents against the same bacterial strain either in a planktonic state or within a biofilm, it could not be guaranteed that an agent would be able to penetrate deep enough to eradicate the planktonic bacteria in a complex biofilm scenario.²³

According to a systematic review and meta-analysis, biofilm is present in over 70% of all hard-to-heal wounds.²⁴ However, there is no point-of-care diagnostic test for wound biofilm, and it is not possible to definitively diagnose it with the naked eye.² Therefore, the presence of biofilm must be assumed after eliminating other possible causes of non-healing. Observation of the wound bed characteristics does enable the clinician to assess the possible presence of biofilm, as well as identify the type of tissue present, such as devitalised or non-viable tissue (*Table 1*).^{3,20,25,26} To reduce any persistent inflammatory state, bioburden should be managed following local biofilm pathways.

Wound-bed preparation

Once a patient with a hard-to-heal wound has been assessed, the wound bed should be prepared to encourage conditions that are conducive to healing.²⁷ This can be achieved with clear and focused guidance from a structured framework, such as TIMERS, TIME and DIME (Box 2).⁸ In TIMERS, interventions should aim to treat the underlying cause and risk factors, based on diagnosis and holistic assessment, as well as address social and patient-related factors. This mnemonic should help clinicians ensure effective wound bed preparation, select the most appropriate interventions and maintain a holistic approach to care (Table 2).⁸

This structured approach can be enhanced by providing patients and their families with bespoke education and involving them in decision-making regarding the interventions. This active communication can improve adherence to treatment plans.

Wound bed preparation is required on a day-to-day basis. Devitalised tissue and biofilm need to be removed at the point of need for the patient, rather than having to wait for specialist intervention—this is in keeping with the guidance that health professionals should be doing the right thing at the right time for the right patient.²⁸ Appropriate management of barriers to healing, such as devitalised tissue, would expedite wound healing, prevent infection, reduce antibiotic resistance, prevent hospital

Box 2. The TIMERS framework⁸

- × Tissue
- × Inflammation/infection
- × Moisture balance
- × Edge/epithelialisation
- × Regeneration/repair of tissue
- × Social and patient-related factors

admissions, minimise the economic burden of wounds and improve quality of life for patients.^{29,30}

Debridement

A key tool in wound-bed preparation to promote healing is debridement. Debridement (distinct from wound cleansing) is the removal of adherent, contaminated or devitalised (non-viable or necrotic) tissue from the wound, including the wound bed, wound edges and periwound skin.³¹

Debridement is especially important as part of an antibiofilm strategy. This is because the tissue removed is likely to be harbouring bacteria and biofilm. Compared with planktonic bacteria, biofilm is more resistant to treatment with antibiotics and topical therapies. Therefore, debridement, which can remove biofilm, can enhance the activity of biocides and create a clean wound bed that is receptive to antimicrobial therapies.³²⁻³⁴

Table 1. Assessing the wound bed to determine the identification of devitalised or non-viable tissue and possible presence of biofilm^{3,20,25,26}

Tissue colour	Characteristics	Cause	Biofilm or local infection	Risks and issues
Red	Appearance of granules (healthy granulation tissue)	Budding or growth of new vessels into the tissue	Unlikely	Some colonisation likely, so healthy granulation should be maintained and biofilm development prevented
Dark red	Friability, bleeds easily	Likely localised biofilm presence	Likely	Likely presence of inflammation/biofilm increases risk of wound infection and prevents advancement of wound edges and wound contraction
Red over-granulation	Overgranulation or raised tissue (proud of wound) without presence of granules	Presence of a foreign body, prolonged inflammation, biofilm, local infection, rubbing of dressing, over-use of occlusive dressings or malignancy	Likely	Likely presence of inflammation/biofilm increases risk of wound infection and prevents epithelialisation and wound contraction; malignancy should be suspected if there is no response to biofilm strategies
Yellow	Slough (which can be dry, fibrinous or wet)	Clearance of cellular debris containing waste products	Likely	Obscuration of true wound depth; obstructed wound contraction; impeded epithelialisation; provision of area of attachment for microbes and biofilm formation; slough likely to continue to develop in presence of biofilm
Black	Black tissue (which can be wet or a dry eschar)	Localised ischaemia causing death of tissue, as a result of hypoxia, pressure or infection	Likely	Obscuration of true wound depth; obstructed wound contraction; impeded epithelialisation; provision of area of attachment for microbes and biofilm formation; potential to mask fluid collection or abscess; wound malodour

Table 2. Applying the TIMERS framework in hard-to-heal wounds⁸

Aspect	Observation	Treatment options	Outcome
Tissue	Devitalised tissue	Debridement (autolytic, sharp, surgical, mechanical, hydrosurgical, debridement pads, enzymatic, larval, ultrasound or laser), CO ₂ , concentrated surfactants	Clean wound bed, debrided devitalised tissue
Inflammation and infection	Signs of inflammation and/or infection, bioburden	Antimicrobials, antibiotics, biofilm pathway, bacterial binding dressings, fluorescence biomodulation, gas plasma, oxygen therapy (hyperbaric and topical), MMP/TIMP management, surfactants	Controlled inflammation, infection and biofilm
Moisture balance	Incorrect moisture balance	NPWT, compression, absorbent dressings	Managed moisture; wound environment conducive to healing
Edge	Edge rolled, epibole or callus; poor advancement of wound edge	Debridement, cyanoacrylate periwound protectants, excision of sclerosed margins, fluorescence biomodulation, wound fillers (for example, collagen)	Reduced wound size, epithelialisation
Tissue regeneration	Slow/stalled closure failing conservative therapy	Amnion/chorion membrane, ECM scaffolds, growth factors, PRP, bioengineered substitutes, NPWT, oxygen therapy (hyperbaric and topical), stem cell therapy, autologous skin graft	Wound closure, tissue repair
Social and patient-related factors	Social situation, patient choice, psychosocial state	Engaging the patient with the care plan; patient, family and/or caregiver education; active listening, motivational literacy, psychoeducation	Understanding patient's belief system, adherence, patient's own goals

Abbreviations: ECM, extracellular matrix; MMP, matrix metalloproteinases; NPWT, negative-pressure wound therapy; PRP, platelet-rich plasma; TIMP, tissue inhibitor of metalloproteinase

Moreover, timely and effective debridement should physically disrupt and suppress the constant cycle of biofilm formation and reformation, preventing planktonic bacteria becoming sessile and establishing biofilm nearby or elsewhere in the body.^{33,35,36}

Before undertaking debridement, practitioners must have completed any relevant training in the chosen technique, and not all practitioners will be competent in the use of surgical and/or sharp debridement methods. Moreover, prior to commencing any type of debridement, capable practitioners must consider a range of factors (Box 3). If there is any concern regarding debridement, a senior member of healthcare staff should be referred to for advice.

Types of debridement

An ideal debridement method would be effective, patient-specific, easy to undertake, low-cost, accessible in all clinical settings and available on a regular basis.³³ However, each of the range of debridement techniques available has its relative advantages and disadvantages that must be considered when choosing the most appropriate debridement option. This choice should be based on a holistic assessment of the patient and their wound and informed by any relevant clinical guidelines and regulations. However, it will also be influenced by the relative cost and availability of different options and the competency of the workforce to deliver them.³¹

Surgical debridement

Surgical debridement involves the use of surgical instruments to remove the devitalised tissue. It is the gold standard method of debridement, and its benefits include fast removal of the devitalised tissue and exploration of the underlying tissue and structures. It has been demonstrated to be effective in stimulating the healing of hard-to-heal wounds when combined with advanced therapies.⁸ Surgical debridement can be performed several times if necessary.

However, surgical debridement is expensive. It must be performed by a multidisciplinary team, including skilled specialist clinicians, usually led by a general, vascular, trauma or plastic surgeon. It also requires a specialist secondary care setting and general anaesthesia, usually

Box 3. Factors to consider before commencing debridement

- × Adherence to biofilm pathway
- × Adherence to local guidance
- × Cause of wound
- × Medications
- × Patient and/or family permission for debridement
- × Presence of ischaemia
- × Tissue type (evidence of necrotic tissue, hard eschar or slough)
- × Wound location and depth

meaning hospital admission. Moreover, hospital admission and surgery carry risks of infection, reduced mobility, lung and bladder stasis (causing chest and urinary infections and/or urinary retention) and blood coagulation, as well as surgical trauma, such as damaged nerves and vessels.³¹

Patients may be unsuitable or unwilling to undergo surgical debridement. This may be due to their general health, quality of life and ability to endure a surgical procedure that may result in a more extensive open wound, as well as their understanding of the risks associated with general anaesthesia and the occurrence of pain.³⁷

Consequently, the implementation of surgical debridement is often limited, and it is usually only considered for the following reasons:

- ✗ Abscess
- ✗ Consideration of skin grafting for tissue repair
- ✗ Risk of damage to blood vessels causing bleeding
- ✗ Failure of other forms of debridement
- ✗ Large, deep wounds requiring debridement before application of other modalities, such as negative pressure wound therapy (NPWT)
- ✗ Major trauma with massive necrosis, such as (large) full-thickness burns and deglovement injuries
- ✗ Need for rapid or major interventions, such as in severe or deep-tissue infection
- ✗ Requirement for reconstructive surgery.³¹

Sharp debridement

Sharp debridement involves the use of scissors, a scalpel or a curette to remove devitalised tissue. Sharp debridement is a fast and extremely efficient way of accurately assessing the extent of the wound, debriding non-viable tissue and managing biofilm.³⁸

Sharp debridement can be performed by a range of healthcare professionals, including nurses, GPs, podiatrists and dermatologists. However, it requires specialist training, and the limited number of nurses with a recognised debridement qualification means that there is often a reliance on medical staff to undertake sharp debridement.

Unlike surgical debridement, sharp debridement can be undertaken in a range of settings, including the patient's home or a local wound, GP or outpatient clinic, and so it does not require hospital admission. However, the need for specialist skills means that it is not always readily available for patients at the point of need and with the regularity needed for biofilm management, especially in community settings.

Sharp debridement comes with the risk of damage to blood vessels, nerves and tendons. It is contraindicated in very large wounds, patients being treated with anticoagulants or an international normalised ratio (INR) above 2.5 (suggesting a raised risk of bleeding).⁸ Aggressive, excisional sharp debridement should not be conducted in patients with peripheral arterial disease or an ankle brachial pressure index (ABPI) below 0.5,⁸ because the lack of perfusion and consequent ischaemia compromises the patient's ability to heal, and surgical or sharp debriding is likely to exacerbate the wound.⁸

Hydrosurgical debridement

Hydrosurgical debridement involves the high-pressure application of a liquid, such as water, saline, polyhexanide or a super-oxidised solution, to wash out the wound (lavage). The effect of high-pressure lavage is similar to sharp debridement, and it can be targeted at a specific area and can remove biofilm.³⁹ However, it can be painful for patients, and it has the potential to increase infection³¹ or disseminate bacteria into the environment due to aerosolisation.⁴⁰ Hydrosurgical debridement requires specialist equipment and professional training, and, thus, it is not suitable in all settings.

Autolytic debridement

Autolytic debridement involves the application of a dressing to provide a moist wound healing environment that should facilitate the body's inherent ability to digest and remove necrotic tissue. These dressings have highly absorptive, moisture-retaining, autolytic and occlusive properties and can be made from materials including hydrogels, hydrocolloids and Hydrofiber. Dressing selection should be based on the wound bed and level of exudate and applied according to manufacturer's instruction and clinical need. Contraindications include known sensitivity to the ingredients of the dressing.

Autolytic debridement involves minimal pain and is relatively easy to use for most clinicians in all healthcare settings. This makes it the most commonly used form of debridement in the UK, and it tends to be the initial approach before other methods are tried.³⁷ However, it is time-consuming³¹ and carries the risk of invasive infection and wound-edge maceration,^{8,31} and there is limited evidence of its effect on biofilm.³³

Autolytic debridement is distinct from use of wet-to-dry gauze to remove devitalised tissue, which has a detrimental effect on granulation tissue and causes pain for the patient and, therefore, is no longer advocated in the UK.

Biological debridement

Biological (or larval) debridement involves use of the larvae (maggots) of the green bottlefly to ingest devitalised tissue and microbes and so stimulate wound healing.³¹ The larvae can be administered free-range (loose) or in a biobag (a special mesh net dressing). Biological debridement is relatively fast and requires limited training, meaning it can be administered in a variety of settings. However, it is comparatively costly, and patients may find it physically uncomfortable and psychologically offputting. Biological debridement is not suitable for very dry wounds or very wet wounds, wounds with exposed blood vessels potentially connected to deep vital organs, malignant wounds or patients with decreased perfusion.⁴¹

Ultrasonic debridement

Ultrasonic debridement involves direct or indirect application of low-frequency energy to assist debridement of devitalised tissue. It is painless, can be selective and has

been demonstrated to reduce microbial bioburden.⁴² However, ultrasonic debridement requires specialist training and equipment, and is relatively expensive for continued use. As with hydrosurgical debridement, it also has the potential to disseminate bacteria into the environment due to aerosolisation.⁴⁰

Mechanical debridement

Mechanical debridement involves use of monofilament cloths, pads or wipes to remove specific tissue types from the wound bed. It should remove slough and devitalised cells, but not necrotic tissue, and it leaves healthy granulation tissue intact.³¹ It can also be used for the removal of hyperkeratotic tissue in the periwound area.⁴³ Mechanical debridement is widely used by specialists and generalists in all settings, due to its ease of use, relatively low cost and lack of requirement for specialist training. However, it is relatively slow, and it is not suitable for dry eschar.

Enzymatic debridement

Enzymatic (or biochemical) debridement involves topical application of enzymes to dissolve necrotic tissue in a wound. It is suitable for non-surgical patients in a variety of settings and can be effectively combined with the promotion of a moist environment for wound healing. However, it is relatively expensive and not recommended for large wounds and infected wounds. These agents have a specific action based on the enzyme (protease) used and the protein it breaks down, such as collagen (collagenase) and elastin (elastase).⁴⁴ In many cases, enzymatic debridement (particularly with collagenase) has been shown to work slowly, and this has limited the number of therapies licensed for use in certain jurisdictions, such as the USA.^{45,46}

Chemical debridement

Chemical debridement uses chemical compounds to remove devitalised tissue and biofilm. In contrast to enzymatic debridement, these chemical compounds denature and aggregate proteins using non-specific, non-enzymatic agents, such as hypochlorous acid and methane sulfonic acid.⁴⁷ Options include ChlorSolv, an amino acid-buffered hypochlorite gel with a chemo-mechanical action, which selectively softens and removes devitalised tissue and biofilm in hard-to-heal venous leg ulcers or diabetic foot ulcers without causing trauma or bleeding.⁴⁸ Another option for chemical debridement is Debrichem (DEBx Medical BV, Amsterdam, Netherlands), which has a desiccant action and is covered in detail in the rest of this supplement.

Other therapies providing a debridement benefit

There are other wound-care therapies that provide a benefit similar to debridement.

NPWT removes exudate from the wound, reduces peri-wound oedema, increases local blood flow and promotes angiogenesis, fibrogenesis and leucocyte and macrophage activity.⁴⁹ It is contraindicated in un-controlled infection or the presence of necrotic tissue, and should be avoided

with active bleeding or in the presence of local ischaemia.⁵⁰ It can be painful for the patient and, therefore, is not always well tolerated, particularly for patients with leg ulcers.

Compression therapy is the gold standard therapy for management of venous leg ulcers,⁵⁰ and it has been demonstrated to have a debridement effect on the wound, together with softening of lipodermatosclerosis.^{51,52} However, these wounds typically also require other forms of debridement techniques.

More aggressive debridement techniques have been recommended in the presence of biofilm.⁵³ It has been suggested that a surgical scrub brush could be considered for a wound bed and periwound skin with dry material, especially eschar, that requires a more aggressive tool; however, this may require local anaesthesia and may also remove viable host tissue, and so it must be undertaken by a senior clinician trained in this technique.²²

Conclusion

Wound bed preparation and biofilm management need to be ongoing parts of wound management. An ideal debridement method needs to be patient-specific, easy to undertake and available in all settings. Surgical debridement is the gold standard, followed by sharp debridement, but these have limitations, in that they require specialist intervention and are not always suitable for the patient and available at the point of clinical need. Other approaches are limited for various reasons, including availability, cost, competency of the practitioner and infection-control risks.

New approaches for debridement techniques need to be developed to enable this vital intervention to be available at the point of need in all clinical settings.

Regular and consistent biofilm management strategies for hard-to-heal wounds, including debridement, will facilitate evidence- and biofilm-based wound management,^{32,33} reducing wound chronicity and its subsequent socio-economic and quality-of-life issues. This is particularly important given its role in maintaining a healthy wound bed in hard-to-heal wounds and preventing biofilm re-formation.

References

1. Leaper D, Assadian O, Edmiston CE. Approach to chronic wound infections. *Br J Dermatol*. 2015; 173(2):351–358. <https://doi.org/10.1111/bjd.13677>
2. Metcalf D, Bowler P. Biofilm delays wound healing: a review of the evidence. *Burns Trauma*. 2013; 1(1):5. <https://doi.org/10.4103/2321-3868.113329>
3. International Wound Infection Institute. Wound infection in clinical practice: international consensus update. Wounds International. 2022. www.woundsinternational.com/resources/details/wound-infection-in-clinical-practice-principles-of-best-practice (accessed 10 January 2023)
4. Bianchi T, Wolcott RD, Peghetti A et al. Recommendations for the management of biofilm: a consensus document. *J Wound Care*. 2016; 25(6):305–317. <https://doi.org/10.12968/jowc.2016.25.6.305>
5. Scottish Intercollegiate Guidelines Network. Management of chronic venous leg ulcers: a national clinical guideline. 2010. <https://www.sign.ac.uk/media/1058/sign120.pdf> (accessed 12 December 2022)
6. Gethin G, Cowman S, Kolbach DN. Debridement for venous leg ulcers. 2015; 2015(9):CD008599. <https://doi.org/10.1002/14651858.CD008599.pub2>
7. Troxler M VKVP. Integrating adjunctive therapy into practice: the importance of recognising 'hard-to-heal' wounds. *World Wide*

- Wounds. 2006. www.worldwidewounds.com/2006/december/troxler/integrating-adjunctive-therapy-into-practice.html (accessed 10 January 2023)
8. Atkin L, Bućko Z, Conde Montero E et al. Implementing TIMERS: the race against hard-to-heal wounds. *J Wound Care*. 2019; 23(S3a):S1–S50. <https://doi.org/10.12968/jowc.2019.28.Sup3a.S1>
 9. Guest JF, Fuller GW, Vowden P. Venous leg ulcer management in clinical practice in the UK: costs and outcomes: health economic impact of VLUs in the UK. *Int Wound J*. 2018; 15(1):29–37. <https://doi.org/10.1111/iwj.12814>
 10. Guest JF, Fuller GW, Vowden P. Diabetic foot ulcer management in clinical practice in the UK: costs and outcomes: Health economic impact of DFUs in the UK. *Int Wound J*. 2018; 15(1):43–52. <https://doi.org/10.1111/iwj.12816>
 11. Martinengo L, Olsson M, Bajpai R et al. Prevalence of chronic wounds in the general population: systematic review and meta-analysis of observational studies. *Ann Epidemiol*. 2019; 29:8–15. <https://doi.org/10.1016/j.annepidem.2018.10.005>
 12. Graves N, Zheng H. The prevalence and incidence of chronic wounds: a literature review. *Wound Pract Res*. 2014; 22(1):4–19
 13. Guest JF, Fuller GW, Vowden P. Cohort study evaluating the burden of wounds to the UK's National Health Service in 2017/2018: update from 2012/2013. 2020; 10(12):e045253. <https://doi.org/10.1136/bmjopen-2020-045253>
 14. Guest JF, Fuller GW, Vowden P. Costs and outcomes in evaluating management of unhealed surgical wounds in the community in clinical practice in the UK: a cohort study. *BMJ Open*. 2018; 8(12):e022591. <https://doi.org/10.1136/bmjopen-2018-022591>
 15. Guest JF, Fuller GW, Vowden P, Vowden KR. Cohort study evaluating pressure ulcer management in clinical practice in the UK following initial presentation in the community: costs and outcomes. *BMJ Open*. 2018; 8(7):e021769. <https://doi.org/10.1136/bmjopen-2018-021769>
 16. Maroz N. Impact of renal failure on wounds healing. 2016; 8(1–3):12–13. <https://doi.org/10.1016/j.jocw.2018.01.004>
 17. Vowden P. Hard-to-heal wounds made easy. *Wounds International*. 2011; 2(4)
 18. Fletcher J, Fumarola S, Haycocks S, King B, Powell G, Vowden K, Young T. Best practice statement: improving holistic assessment of chronic wounds. *Wounds UK*. 2018. www.wounds-uk.com/download/resource/6596 (accessed 10 January 2023)
 19. Besser M, Dietrich M, Weber L, Rembe JD, Stuermer EK. Efficacy of antiseptics in a novel 3-dimensional human plasma biofilm model (hpBIOM). *Sci Rep*. 2020; 10(1):4792. <https://doi.org/10.1038/s41598-020-61728-2>
 20. Percival SL, McCarty SM, Lipsky B. Biofilms and wounds: an overview of the evidence. *Adv Wound Care*. 2015; 4(7):373–381. <https://doi.org/10.1089/wound.2014.0557>
 21. Wu Y-K, Cheng N-C, Cheng C-M. Biofilms in chronic wounds: pathogenesis and diagnosis. *Trends Biotechnol*. 2019; 37(5):505–517. <https://doi.org/10.1016/j.tibtech.2018.10.011>
 22. Murphy C, Atkin L, Swanson T et al. Defying hard-to-heal wounds with an early antibiofilm intervention strategy: wound hygiene. *J Wound Care*. 2020; 29(S3b):S1–S26. <https://doi.org/10.12968/jowc.2020.29.Sup3b.S1>
 23. Rembe JD, Fromm-Dornieden C, Böhm J, Stuermer EK. Influence of human acute wound fluid on the antibacterial efficacy of different antiseptic polyurethane foam dressings: an in vitro analysis. *Wound Rep Regen*. 2018; 26(1):27–35. <https://doi.org/10.1111/wrr.12612>
 24. Malone M, Bjarnsholt T, McBain AJ et al. The prevalence of biofilms in chronic wounds: a systematic review and meta-analysis of published data. *J Wound Care*. 2017; 26(1):20–25. <https://doi.org/10.12968/jowc.2017.26.1.20>
 25. Harker J, Moore K. Tissue management and wound pathophysiology. *Br J Community Nurs*. 2004; 9(S9):5–11
 26. World Union of Wound Healing Societies. Principles of best practice: wound infection in clinical practice (an international consensus). 2008. www.woundsinternational.com/resources/details/wound-infection-in-clinical-practice-principles-of-best-practice (accessed 10 January 2023)
 27. Chi YW, Raffetto JD. Venous leg ulceration pathophysiology and evidence based treatment. 2015; 20(2):168–181. <https://doi.org/10.1177/1358863x14568677>
 28. NHS. Getting it Right First Time (GIRFT). 2017. <https://gettingitrightfirsttime.co.uk> (accessed 10 January 2023)
 29. NHS England, NHS Improvement. The National Wound Care Strategy Programme. 2018. www.nationalwoundcarestrategy.net/about-the-nwscsp (accessed 10 January 2023)
 30. Fletcher J, Edwards-Jones V, Fumarola S et al. Best practice statement: antimicrobial stewardship strategies for wound management. *Wounds UK*. 2020. www.wounds-uk.com/resources/details/best-practice-statement-antimicrobial-stewardship-strategies-wound-management (accessed 10 January 2023)
 31. Strohal R, Dissemmond J, Jordan O'Brien J, Piaggese A, Rimdeika R, Young T, Apelqvist J. Debridement: an updated overview and clarification of the principle role of debridement. *J Wound Care*. 2013; 22(1):5. <https://doi.org/10.12968/jowc.2013.22.Sup1.S1>
 32. Association for the Advancement of Wound Care. Advancing your practice: understanding wound infection and the role of biofilms. 2008. <https://gneaupp.info/wp-content/uploads/2014/12/wound-infection-and-the-role-of-biofilms.pdf> (accessed 10 January 2023)
 33. Wolcott RD, Kennedy JP, Dowd SE. Regular debridement is the main tool for maintaining a healthy wound bed in most chronic wounds. *J Wound Care*. 2009; 18(2):54–56. <https://doi.org/10.12968/jowc.2009.18.2.38743>
 34. Smolders D, Hendriks B, Rogiers P, Mul M, Gordts B. Acetic acid as a decontamination method for ICU sink drains colonized by carbapenemase-producing *Enterobacteriaceae* and its effect on CPE infections. *J Hosp Infect*. 2019; 102(1):82–88. <https://doi.org/10.1016/j.jhin.2018.12.009>
 35. Metcalf D, Bowler P, Parsons D. Wound biofilm and therapeutic strategies. In: Dhanasekaran D, Thajuddin N, eds. *Microbial biofilms: importance and applications*. London: InTech; 2016
 36. Hurlow J, Bowler Pg. Potential implications of biofilm in chronic wounds: a case series. *J Wound Care*. 2012; 21(3):109–119. <https://doi.org/10.12968/jowc.2012.21.3.109>
 37. Vowden K, Vowden P. Debridement made easy. *Wounds UK*. 2011. www.wounds-uk.com/resources/details/debridement-made-easy (accessed 10 January 2023)
 38. Percival SL, Suleman L. Slough and biofilm: removal of barriers to wound healing by desloughing. *J Wound Care*. 2015; 24(11):498–510. <https://doi.org/10.12968/jowc.2015.24.11.498>
 39. Allan N, Olson M, Nagel D, Martin R. The impact of hydrosurgical debridement on wounds containing bacterial biofilms. 2011. <https://tinyurl.com/ycke49fz> (accessed 10 January 2023)
 40. Bowling FL, Stickings DS, Edwards-Jones V, Armstrong DG, Boulton AJM. Hydrodebridement of wounds: effectiveness in reducing wound bacterial contamination and potential for air bacterial contamination. *J Foot Ankle Res*. 2009; 2:13. <https://doi.org/10.1186/1757-1146-2-13>
 41. Gottrup F, Jørgensen B. Maggot debridement: an alternative method for debridement. *Eplasty*. 2011; 11:e33
 42. Ennis WJ, Foremann P, Mozen N, Massey J, Conner-Kerr T, Meneses P. Ultrasound therapy for recalcitrant diabetic foot ulcers: results of a randomized, double-blind, controlled, multicenter study. *Ostomy Wound Manage*. 2005; 51(8):24–39
 43. Pidcock L, Jones H. Use of a monofilament fibre debridement pad to treat chronic oedema-related hyperkeratosis. *Wounds UK*. 2013; 9(3):85–88
 44. Shi L, Carson D. Collagenase Santyl ointment: a selective agent for wound debridement. *J Wound Ostomy Continence Nurs*. 2009; 36(S6):S12–16. <https://doi.org/10.1097/WON.0b013e3181bfdd1a>
 45. McFarland A, Smith F. Wound debridement: a clinical update. *Nurs Stand*. 2014; 28(52):51–58. <https://doi.org/10.7748/ns.28.52.51.e9171>
 46. Thomas DC, Tsu CL, Nain RA, Arsat N, Fun SS, Sahid Nik Lah NA. The role of debridement in wound bed preparation in chronic wound: a narrative review. *Ann Med Surg*. 2021; 71:102876. <https://doi.org/10.1016/j.amsu.2021.102876>
 47. Block MS, Rowan BG. Hypochlorous Acid: A Review. *J Oral Maxillofac Surg*. 2020; 78(9):1461–1466. <https://doi.org/10.1016/j.joms.2020.06.029>
 48. Atkin L. Introducing a new approach to debridement and wound bed preparation. *J Wound Care*. 2022; 31(8 S1):S5–S12
 49. Lorée S, Domp Martin A, Penven K, Harel D, Leroy D. Is vacuum assisted closure a valid technique for debriding chronic leg ulcers? *J Wound Care*. 2004; 13(6):249–252. <https://doi.org/10.12968/jowc.2004.13.6.26629>
 50. Singh S. Role of negative pressure wound therapy in plastic surgery—its basics, indications and contraindications. 2014. <https://tinyurl.com/55m4h7w3> (accessed 10 January 2023)
 51. O'Meara S, Cullum N, Nelson EA, Dumville JC. Compression for venous leg ulcers. *Cochrane Database Syst Rev*. 2012. <https://doi.org/10.1002/14651858.CD000265.pub3>
 52. Mauck KF, Asi N, Elraiyah TA et al. Comparative systematic review and meta-analysis of compression modalities for the promotion of venous ulcer healing and reducing ulcer recurrence. *J Vasc Surg*. 2014; 60(S2):71S–90S.e71–72. <https://doi.org/10.1016/j.jvs.2014.04.060>
 53. Schultz G, Bjarnsholt T, James GA et al. Consensus guidelines for the identification and treatment of biofilms in chronic nonhealing wounds. *Wound Rep Regen*. 2017; 25:744–757. <https://doi.org/10.1111/wrr.12590>

Introducing a desiccant debridement agent: as effective as a blade, as easy as a pad

Michel Hermans

Biofilms and devitalised (sloughy and necrotic) tissue have been shown to delay wound healing and play a role in wound chronicity.^{1,2} Therefore, these are problems that need to be addressed, and the removal of biofilms and necrotic tissue is an essential step in facilitating wound healing. However, biofilms, which have been found in at least 80% of wound biopsies,³ are especially resistant to immune defences, antibiotics and antiseptics, making them difficult to treat with medication alone.⁴

Biofilms and necrotic tissue are most effectively removed with regular and vigorous debridement.⁵ This can be achieved with various methods, each with its own benefits and drawbacks.¹ For example, surgical debridement is fast and effective, but it is also invasive, relatively expensive and dependent on particular expertise.⁶

Debrichem (DEBx Medical BV, Amsterdam, Netherlands) is a topical desiccation agent designed to overcome the disadvantages of traditional debridement options, particularly those of surgical debridement. Compared with other options, this method of chemical debridement is easy to use, cost-effective and quick to apply, and it typically only requires a single application.⁷

Mechanism of action

Debrichem is an active gel containing methane sulfonic acid, which has rapid desiccating (hygroscopic) properties. Contact with water in the wound bed causes an immediate reaction, producing around 1500 KJ/mol of energy. This is potent enough to destroy virtually all biochemical bonds in any infected and devitalised tissue, leading to its swift desiccation and oxidation.⁸⁻⁹ Over the next 1–3 days, these desiccated and denatured tissues and other organic compounds should coagulate together and separate from the underlying wound bed, leaving it prepared for the development of granulation tissue. The presence of granulation tissue in the wound bed is essential both for healing by secondary intention (how most hard-to-heal wounds heal) and for closing a wound with a skin graft.¹⁰

Application

Patients undergoing treatment with Debrichem should first receive topical analgesia appropriate to their needs

and the location of the wound. This is because Debrichem's acidic action typically causes pain during and briefly after application—comparable to the pain caused during surgical debridement.

Following basic cleaning of the wound and periwound area, the single-use vial of Debrichem should be applied over the wound bed and 1cm of the periwound skin (*Figure 1*). After being left in place for 60 seconds, the gel is diluted and removed by rinsing with saline or sterile water. This short exposure period assures that the desiccant action does not damage the periwound skin, as the stratum corneum has a substantially lower water content than the tissues beneath it. Debrichem must be used within its indications to avoid harming viable cells.

After application, there is no specific requirement for dressings or other interventions, and these can be used at the clinician's discretion.

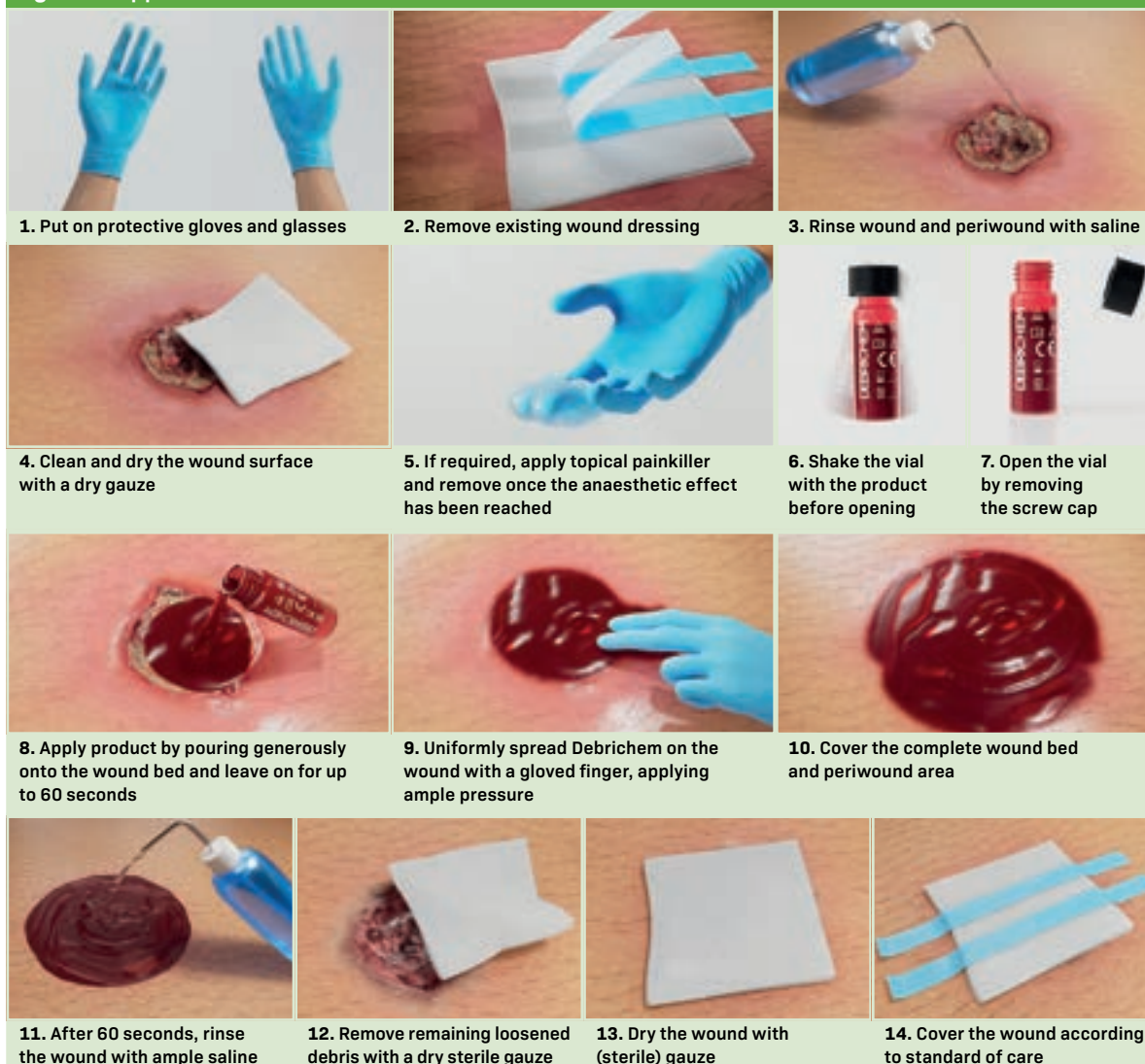
Indications and contraindications

Debrichem is indicated for non-surgical debridement and treatment of non-surgical hard-to-heal wounds that are infected and contain biofilm and/or necrotic tissue. Several contraindications apply, including ischaemic wounds before effective revascularisation; neoplastic wounds; underlying abscesses or fasciitis that require incision/excision and drainage; underlying osteomyelitis; exposed cartilage and/or intolerance or allergies to any of the product ingredients.

Supporting evidence

A UK cost-effectiveness study that compared Debrichem with standard of care with standard of care alone over 12 months in patients with hard-to-heal venous leg ulcers found that it improved health-related quality of life, increased probability of healing by 75% and reduced overall treatment costs by up to 57%.¹¹ In addition, case-series audits indicate that Debrichem is a fast, effective and easy-to-use alternative to surgical debridement for treating hard-to-heal wounds containing biofilm and/or necrotic tissue.¹²⁻¹⁶

These data on clinical and cost efficacy suggest that this topical desiccation agent can rapidly eliminate biofilm and devitalised tissue to reduce the chance of infection and facilitate granulation and wound healing.

Figure 1. Application of Debrichem

References

1. Ayello EA, Cuddigan JE. Debridement: controlling the necrotic/cellular burden. *Adv Skin Wound Care*. 2004; 17(2):66–75. <https://doi.org/10.1097/00129334-200403000-00012>
2. Percival SL, Vuotto C, Donelli G, Lipsky BA. Biofilms and wounds: an identification algorithm and potential treatment options. *Adv Wound Care*. 2015; 4(7):389–397. <https://doi.org/10.1089/wound.2014.0574>
3. Malone M, Bjarnsholt T, McBain AJ et al. The prevalence of biofilms in chronic wounds: a systematic review and meta-analysis of published data. *J Wound Care*. 2017; 26(1):20–25. <https://doi.org/10.12968/jowc.2017.26.1.20>
4. Bianchi T, Wolcott RD, Peghetti A et al. Recommendations for the management of biofilm: a consensus document. *J Wound Care*. 2016; 25(6):305–317. <https://doi.org/10.12968/jowc.2016.25.6.305>
5. Riley WB Jr. Wound healing. *Am Fam Physician*. 1981; 24(5):107–113
6. Gordon KA, Lebrun EA, Tomic-Canic M, Kirsner RS. The role of surgical debridement in healing of diabetic foot ulcers. *Skinmed*. 2012; 10(1):24–26
7. Guest JF, Deanesi V, Segalla A. Cost-effectiveness of Debrichem in managing hard-to-heal venous leg ulcers in the UK. *J Wound Care*. 2022; 31(6):480–491. <https://doi.org/10.12968/jowc.2022.31.6.480>
8. NIST Chemistry WebBook. Methanesulfonic acid. 2021. <https://tinyurl.com/mr4hthun> (accessed 22 February 2022)
9. Hermans, MHE. Physico-chemical interaction of a debriding acid with biofilm. Presentation at the Symposium for Advanced Wound Care, National Harbor, MD, USA, 2023
10. Bignozzi AC, Cogo A, Carinci F. Compositions for removing necrotic or infected tissues from body lesions and from oral cavity (patent pending). Patent Cooperation Treaty (Nr PCT/IB2019/051146). 2020
11. Guest JF, Deanesi V, Segalla A. Cost-effectiveness of Debrichem in managing hard-to-heal venous leg ulcers in the UK. *J Wound Care*. 2022; 31(6):480–491. <https://doi.org/10.12968/jowc.2022.31.6.480>
12. Cogo A, Quint BJ, Bignozzi CA. Restarting the healing process of chronic wounds using a novel desiccant: a prospective case series. *Wounds*. 2021; 33(1):1–8
13. Cogo A, Bignozzi AC, Hermans MH et al. A desiccation compound as a biofilm- and necrosis-removing agent: a case series. *J Wound Care*. 2022; 31(10):816–22. <https://doi.org/10.12968/jowc.2022.31.10.816>
14. Cogo A, Quint BJ, Bignozzi CA. Restarting the healing process of chronic wounds using a novel desiccant: a prospective case series. *Wounds*. 2021; 33(1):1–8
15. Hermans MHE. Combining an acidic compound and NPWT: debridement and granulation in leg and foot ulcers. *Ann Case Rep*. 2023; 7:1101. <https://doi.org/10.29011/2574-7754.101101>
16. Schwarzer S, Radzieta M, Jensen SO, Malone M. Efficacy of a topical wound agent methanesulfonic acid and dimethylsulfoxide on in vitro biofilms. *Int J Mol Sci*. 2021; 22(17):9471. <https://doi.org/10.3390/ijms22179471>

Case studies

Case study 1. Right venous leg ulceration treated with Debrichem

Priti Bhatt

Background

Austin was a 58-year-old man with a history of bilateral venous leg ulcers (VLUs). These had a major impact on his quality of life, causing pain, malodour and high levels of exudate, leading to isolation, anxiety and depression.

Austin also had a history of anaemia (iron and folic acid), coeliac disease, lupus-anticoagulant positivity and osteopenia. For a while, Austin had become dependent on alcohol after leaving the armed forces, but he has since recovered from the addictive behaviour. He had been taking citalopram 40 mg, warfarin, co-codamol 30/500 three times a day and oral morphine as needed, as well as antidepressants and sleeping tablets when his leg ulcers were at their worst in 2017.

Austin's VLUs were first diagnosed in May 2015, at a complex wound clinic led by a tissue-viability team. A standardised Doppler assessment following best practice guidelines obtained ABPI results of 1.21 on the left and 1.19 on the right leg. The VLUs were thought to likely be a result of underlying deep vein thrombosis (DVT).

Since diagnosis, the VLUs were variously treated with honey gel, honey tulle, Hydrofiber, metronidazole gel, silver Hydrofiber, silver sulfadiazine, superabsorbent pads, zinc paste and 50:50 white paraffin ointment. These were all secured with two-layer compression bandages or Velcro wraps. Oral morphine was required before dressing changes.

Following diagnosis, Austin attended the complex wound clinic once a week, with vascular consultant reviews around every 6 months. By July 2016, the VLUs had healed, and he was discharged with below-knee compression hosiery.

However, by April 2017, Austin had again developed bilateral VLUs, and they were causing severe pain and reduced mobility, which resulted in him experiencing falls and living in a micro-environment in his kitchen. That month, he was admitted to hospital after overdosing on analgesia. In June 2018, Austin was admitted for a venogram and inferior vena cava stent reconstruction. He saw an improvement in symptoms until August 2018, when the cycle of recurrent wound infections requiring antibiotics started. Following this, in December 2019, he

had a bilateral iliac venogram and a stent to his left leg. He continued to have full compression bandages applied to both legs.

In 2020, the left leg had healed, but the right leg remained static. He had heavy growth of *Staphylococcus aureus* and mixed coliforms, and so required antibiotics (flucloxacillin 500 mg four times a day for 2 weeks) roughly every 3 months. The last course was completed in September 2021.

Presentation

By December 2021, Austin was attending the wound clinic once a week. His right leg was being treated with full compression bandages, steroid cream (for irritated, dry, red areas of varicose eczema around the wound), superabsorbent pads (for moderate-to-high exudate), 50:50 white paraffin ointment (to moisturise the whole leg) and zinc paste (to soothe very dry and itchy skin around the heel and ankle). Between clinic visits, he was redressing his wound himself due to a lack of trained practice nurses at his GP surgery. This meant he had to use Velcro wraps instead of two-layer compression bandages until the next clinic visit, as wraps are easier to self-apply than bandaging, which requires specialist training. Consequently, half the time, it was not possible to monitor or guarantee consistent maintenance of the ideal level of compression to address underlying venous issues. Austin would remove the wraps to moisturise his leg each day, and in clinic appointments it was noted that the Velcro straps at the top of the wrap were not always pulled tightly enough.

At this time, Austin was leading a very active lifestyle and volunteered daily with the homeless, which meant he was regularly on his feet for long periods. He was taking citalopram, warfarin and co-codamol 30/500.

On 2 December 2021, Austin was assessed at the complex wound clinic. His unilateral right VLU measured 10.5×8.0 cm (*Figure 1*). Around 60% of the wound bed was very dark red, purulent and friable, while the other 40% was covered with thin layers of yellow slough. It was stained with blood and producing a high level of serosanguinous exudate. The wound edges were very dark purple, with

Priti Bhatt, Community Tissue Viability Nurse Specialist Lead, Guy's & St Thomas' NHS Foundation Trust
Emma Bennett, Senior Sister for Tissue Viability, University Hospital of North Midlands
Sarah Molden, Vascular Nurse Specialist, University Hospital of North Midlands
Katie Leek, Clinical Lead for Tissue Viability and Continence, University Hospital of North Midlands
Annabelle Mooney, Nurse Specialist, Bradford District Care NHS Foundation Trust
Hayley Turner-Dobbin, Clinical Delivery Lead, Accelerate

slight maceration to the periwound skin. It was evident that the wound had failed to progress for at least the past 12 months, despite trying various primary dressings to keep infection at bay and promote healing.

Commencement

It was decided to try Austin on a new option for chemical debridement, Debrichem (DEBx Medical BV, Amsterdam, Netherlands), alongside his usual care, as it was understood to have the potential to minimise or stop the constant cycle of re-infection and antibiotics. The tissue viability nurses reviewed Austin's medical history to ascertain suitability for Debrichem, and they explained to him that it was a one-off application that could stop the re-infection cycle but that it could be painful for the first few minutes. He was very keen to try it and signed his consent.

Austin was not swabbed before starting Debrichem, as there were no systemic signs of infection. Neither was he given any analgesia, as the team was new to using Debrichem and had not yet received advice from the manufacturer to use 5% lidocaine and prilocaine cream.

As usual, Austin's right leg was cleansed with antimicrobial lotion and water and then dried. As per instructions, Debrichem was then applied with a gloved finger to the wound and surrounding edges. The solution was left in place for 60 seconds before being washed off with at least a litre of free-flowing saline. Immediately after, the wound bed had changed colour and appeared very dark and dry. Austin reported a burning sensation with a 10/10 visual analogue scale (VAS) pain score during application, which

reduced to 8/10 immediately after removal and 4/10 1 hour later after the dressing had been completed.

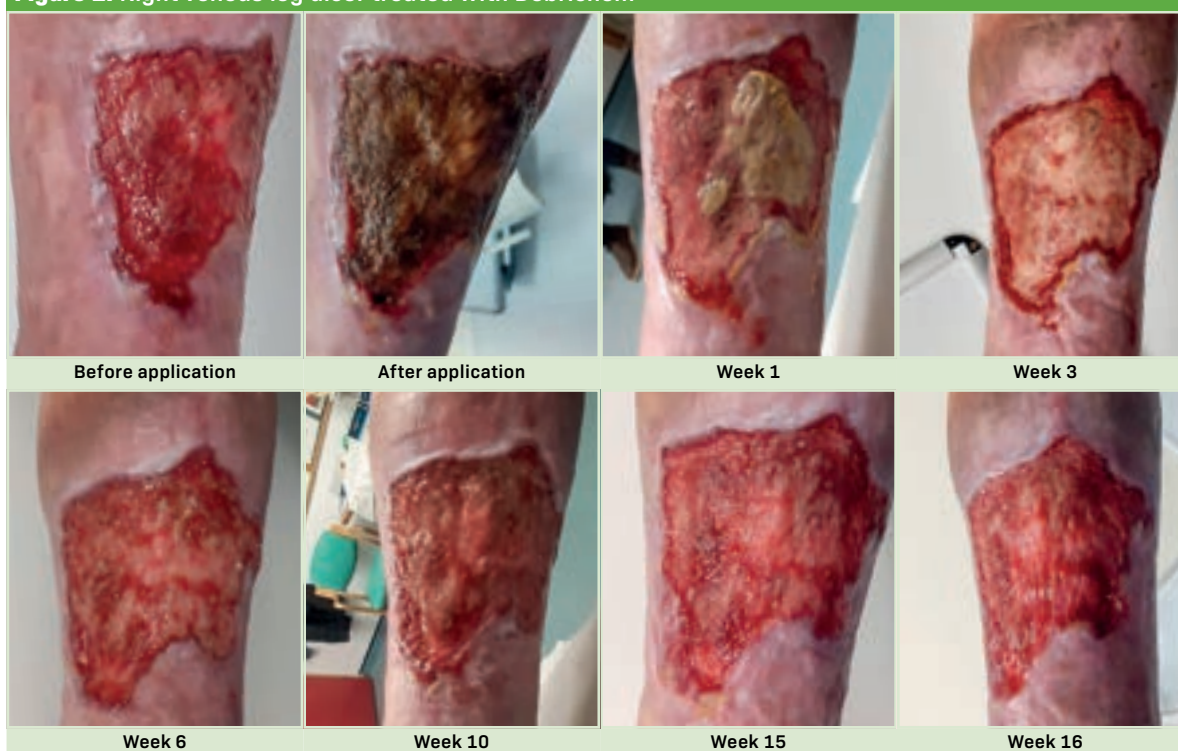The wound bed was covered with a simple non-adherent contact layer and dressed as usual. Austin was advised to continue his usual care plan and simple dressing routine (non-adherent contact layer, super-absorbent pad and two-layer compression bandages alternating with Velcro wraps). He was also advised to follow clinic practice in lining the plastic bowl he uses to wash his leg with a clean bag to minimise bacterial contamination.

Follow-up

For the next 15 weeks, Austin had weekly follow-ups in clinic, where his wound and leg were washed, dried and treated. From day 3, Austin managed to change the dressing himself, and he noted moderate-to-heavy purulent exudate; subsequent examinations found consistent moderate serosanguineous exudate, unless otherwise noted.

- ✗ At week 1, there was a thick layer of desiccated slough in the central part of the wound (whereas, before the application, a layer of moist slough had covered the whole wound bed). This desiccated area was now surrounded by healthier granulation tissue, suggesting that autolysis was taking place. The rest of the wound bed and surrounding skin appeared much healthier in colour and was granulating, without the shiny appearance of biofilm over its surface. There were no signs of systemic or local infection.
- ✗ At week 2, there was a thin slough layer in the centre of the wound, and the wound edges were slightly rolled at

Figure 1. Right venous leg ulcer treated with Debrichem



the top; the periwound skin was pink and healthy and remained so throughout follow-up

- ✗ At week 6, the thin yellow slough had reduced to around 30%, the granulation had increased to 70%, the edges had flattened, the wound was up to surface level and there was moderate purulent exudate—at this point, Austin's primary dressing was changed from a non-adherent contact layer to a zinc bandage to alleviate the persistent itch that had become his main concern
- ✗ At week 8, there was 90% granulation and 10% very thin slough, while the wound edges showed slight maceration
- ✗ At week 10, there was still thin yellow slough, healthy granulation and macerated wound edges
- ✗ At weeks 12 and 14, there was a thin layer of slough covering the wound, no obvious signs of infection and slightly macerated wound edges
- ✗ At week 16, the slough had decreased, the edges were epithelialising and exudate levels had become low-to-moderate.

Outcome

In the weeks after application of Debrichem, Austin reported greatly reduced pain, with no need for analgesia, and no malodour, which significantly improved his quality of life. The wound bed reduced slightly in height from 12 cm to 9 cm but stayed around 8–8.5 cm wide. However, the wound bed showed a reduction in exudate and slough, as well as being generally healthier in appearance, with an increase in healthy granulation tissue up to surface level. The wound edges had also improved and were no longer slightly rolled. Austin has not required oral antibiotics for the past 5 months since treatment with Debrichem, which he was pleased about, as it had been affecting his warfarin levels.

Discussion

Chemical debridement with Debrichem has the advantage of not requiring hospital admission or the specialist training required for sharp and surgical debridement. That said, it should be carried out by a trained professional, such as a tissue viability nurse.

The team found Debrichem to be quick and easy to apply. However, the patient reported a 10/10 level of burning pain during the brief application period before the solution was washed off with lots of fast-flowing

Summary 1 . Right venous leg ulceration treated with Debrichem

Patient	58-year-old man
Medical history	Anaemia (iron and folic acid), coeliac disease, lupus-anticoagulant positivity, osteopenia, recovery from alcohol addiction
Medication	Citalopram, warfarin, co-codamol, oral morphine as needed; steroid cream, 50:50 white paraffin ointment
Wound location	Right leg (historically bilateral)
Wound history (time before presentation)	6.5 years, diagnosis of bilateral ulceration linked to possible deep vein thrombosis; 5.5 years, temporary healing; 3.5 years, venogram and inferior vena cava stent reconstruction, with improvement in symptoms; 3.3 years, start of recurrent infections; 2 years, bilateral iliac venogram and stent to left leg
Holistic impacts	Pain, anxiety, depression, social isolation
Rationale for Debrichem	Recurrent infection requiring antibiotics, no progression despite other treatments for at least 12 months
Regimen on presentation	Zinc paste, superabsorbent pads, full compression bandages (alternating with Velcro wraps)
Other previous treatments	Honey gel, honey tulle, Hydrofiber, metronidazole gel, silver Hydrofiber, silver sulfadiazine
Post-Debrichem regimen	Non-adherent contact layer, second contact layer, superabsorbent pads, full compression bandages (alternating with Velcro wraps)
Analgesia	None
Pain (visual analogue scale)	10/10 on application, 8/10 immediately after removal, 4/10 after 1 hour
Key outcomes	Slough on wound bed from 40% at presentation to 30% at week 6 and 10% at week 8; wound size from 10.5×8.0 cm at presentation to 9.0×8.5 cm at week 10; exudate level from high at presentation to moderate at week 6

sterile water or saline. This means that clinicians should ideally use a topical analgesic and be prepared to rapidly wash off the solution after 60 seconds, without any delay to avoid unnecessary pain.

Austin's clinical outcomes gave the impression that Debrichem reduced the bacterial burden on the wound bed, suggesting that this treatment can be recommended for disrupting biofilm and the cycle of re-infection in hard-to-heal wounds.

Case study 2. Bilateral venous leg ulceration treated with Debrichem

Priti Bhatt

Background

Bill was a 67-year-old man, recently retired from being a council worker, with a history of hard-to-heal VLUs on both inner ankles (right and left medial malleoli areas).

Bill had been diagnosed with hypertensive disease in October 2005, obesity in July 2006 and well-controlled type 2 diabetes mellitus in April 2019, and he was taking

amlodipine 5 mg, atorvastatin 40 mg and losartan 25–50 mg daily. He had had a total right hip replacement in April 2019 and was fully mobile. Since 2013, he had also had chronic bilateral pitting oedema in both legs and feet, as well as prominent varicose veins on both thighs since February 2016, which can be a precursor of VLUs. He had been issued with compression hosiery to manage

Summary 2. Bilateral venous leg ulceration treated with Debrichem	
Patient	67-year-old male
Medical history	Hypertension, obesity, type 2 diabetes, total right hip replacement, chronic bilateral pitting oedema, bilateral varicose veins
Medication	Amlodipine, atorvastatin, losartan; 50:50 white paraffin ointment
Wound location	Right and left medial malleoli areas
Wound history (time before presentation)	8 years, start of ulceration; 2.5 years, temporary healing for 3 (right) and 5 (left) months, without adherence to compression, followed by repeat infections requiring antibiotics
Holistic impacts	Pain, embarrassment, social isolation
Rationale for Debrichem	Recurrent infection requiring antibiotics, no progression despite other treatments for 19 months
Regimen on presentation	Zinc paste, superabsorbent pads, full compression bandages
Other previous treatments	Silver sulfadiazine, silver Hydrofiber, honey tulle, compression wraps for self-care, class 2 compression hosiery after healing
Post-Debrichem regimen	Non-adherent contact layer (later changed to zinc paste), superabsorbent pads, full compression bandages
Analgesia	None
Pain (visual analogue scale)	2/10 on presentation, 10/10 during application, 6/10 after 5 minutes, 4/10 after dressing
Key outcomes	Wound size from 4.5×2.5cm at presentation to 3.0×2.0cm at week 18 (right) and from 2.0×1.5cm at presentation to 2.0×1.0cm at week 18 (left); exudate level from moderate at presentation to low at week 14

his oedema, but he had not been adherent with wearing these daily. He also had dry hard skin around his heels, scar tissue from previous ulceration episodes and a capillary refill of less than 3 seconds. An assessment in September 2021 showed two biphasic dorsalis pedis arteries, mild lichenified skin on the left toes and no loss of sensation in either foot (sensate to 10g monofilament at all sites).

Bill's VLUs were first diagnosed in 2013, with Doppler ABPI results of 1.10 (right) and 1.11 (left), which were in the normal range for full compression. He was referred to the vascular team for review. In the years since, the VLUs have varied considerably in their presentation and consequent impact on his activities of daily living. When they presented with malodour, high exudate levels or infection, they caused pain and embarrassment, reducing Bill's willingness to socialise. Bill's VLUs temporarily healed in February 2019, but the VLU on his right ankle recurred in June 2019 and on his left ankle in August 2019. In the 2 years since then, these VLUs have been prone to infection, despite the use of topical antimicrobials and required various oral and topical antibiotics. He was being prescribed antibiotics on average every 6 months.

Bill's legs were washed initially with a bucket of warm water and antimicrobial emollient solution or occlusive ointment and subsequently with water and antimicrobial wash lotion. This was followed by thorough drying and application of 50:50 white paraffin ointment to all intact skin on the legs and feet, as well as urea cream on hard skin around the heel.

Bill's VLUs were cleansed with a wound irrigation solution. Over the years, he had been treated with a variety of different primary antimicrobial dressings, often for prolonged periods. These included silver sulfadiazine, silver Hydrofiber, honey tulle and zinc paste, the latter to soothe the patient and maintain a moist wound healing environment. These were supported with a secondary dressing of superabsorbent pads and either two-layer compression bandages or compression wraps for self-care.

After Bill's VLUs had healed in February 2019, he was advised to wear class 2 compression hosiery on both legs, reinforced with a leaflet explaining the rationale for this. However, he did not adhere to this recommendation, feeling that he did not require compression once his legs felt normal. After the VLUs recurred later that year, he realised that this had not been the right thing to do.

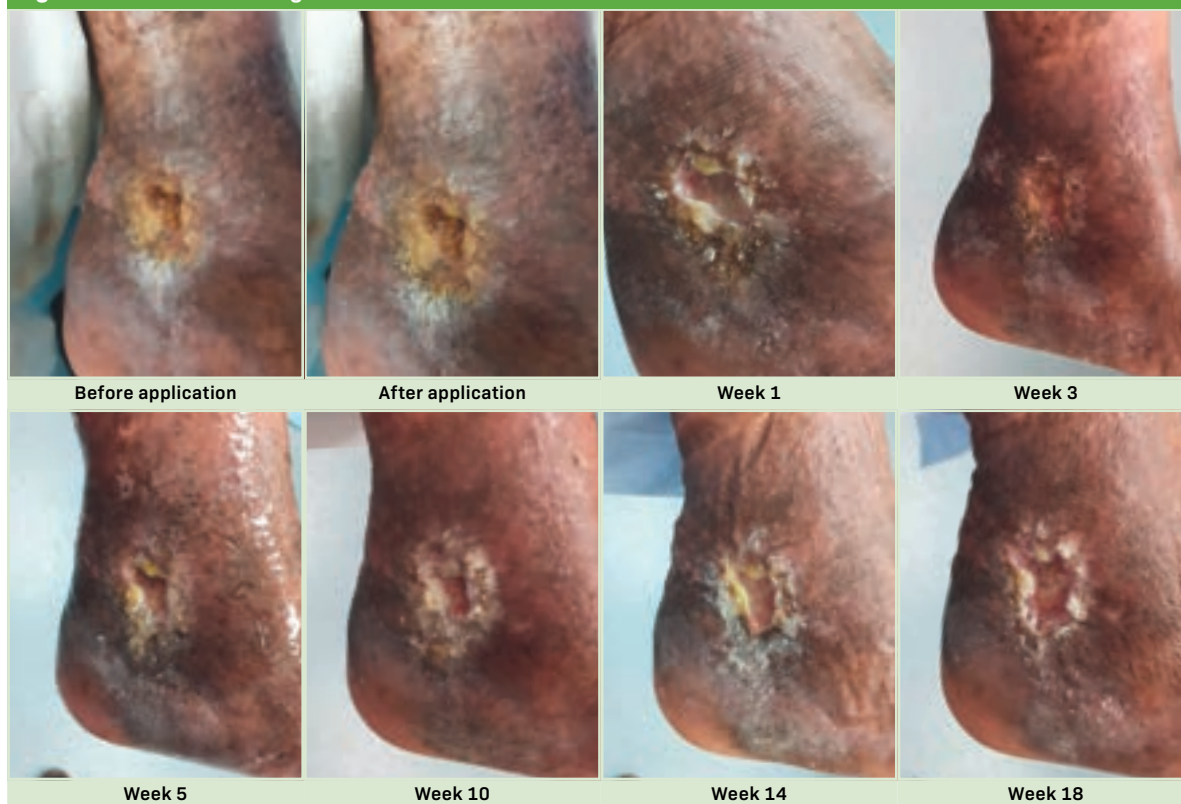
Bill's dressing was usually changed twice weekly, once in clinic and once at home by the patient. However, from February to May 2020, the first COVID-19 lockdown closed the clinic and limited the vascular service to telephone reviews. Bill was recommended to continue compression therapy at home via self-care with compression wraps. Over this period, the wounds deteriorated and became slightly larger and deeper, but their condition stabilised after the clinic reopened in May 2020.

Bill found the bandages and wraps hot and constricting, and they limited his footwear options. Consequently, he would tend to remove them for a few hours before clinic appointments, even though he was advised not to do this in an information leaflet given at the start of treatment and by the clinician at every appointment.

Presentation

On 2 December 2021, Bill attended a weekly review at a wound advisory clinic. The right VLU measured 2.5×4.5cm, while the left wound was 1.5×2cm (*Figures 2a and 2b*). Both wounds had a shiny appearance, slight malodour and yellow slough covering 100% of the wound bed. The right VLU was producing a moderate amount, and the left a low amount, of purulent exudate, and there was slight maceration of the surrounding skin at the lower end of both wounds. The edges of both ulcers were raised, with build-up of hard skin that was very difficult to remove. Bill's self-reported pain VAS score was low, at 2/10. His Doppler results were in the normal range for full compression therapy.

Over the past 19 months, various primary dressings had been tried for at least 4 weeks to try to promote healing, but these had all been unsuccessful. Because of

Figure 2a. Left venous leg ulcer treated with Debrichem

the wound's static nature and cycle of reinfection, it was surmised that this was likely the result of biofilm formation. On presentation, he was being treated with zinc paste, superabsorbent pads, full compression bandages and 50:50 white paraffin ointment.

Commencement

After discussing Bill's medical history to ascertain suitability, it was decided to offer Bill a trial of Debrichem. The team explained to Bill the process and rationale for using this one-off chemical debridement treatment, including its potential to cause a lot of pain for the first few minutes. Bill was very keen to try it, in the hope that it would stop the constant cycle of reinfection and antibiotics, and so he signed his consent.

Bill's legs were washed and dried as normal. Following instructions and guidance from representatives of the manufacturer (DEB) and distributor (Edge Medical) in attendance—Debrichem was then applied to the wound and surrounding edges, left in place for 35 seconds and then washed off using normal saline. Bill initially opted to try the treatment on his right ankle wound only. However, after the right ankle was treated, he then chose to have Debrichem applied to his left ankle wound as well, wishing to 'Get the painful part over in one session, if it is beneficial to the wounds'. Immediately after treatment, the wound beds had become darker in colour and dry looking. After this, the leg was moisturised as

normal, and the wound was dressed with a non-adherent contact layer, superabsorbent pad and full compression bandages.

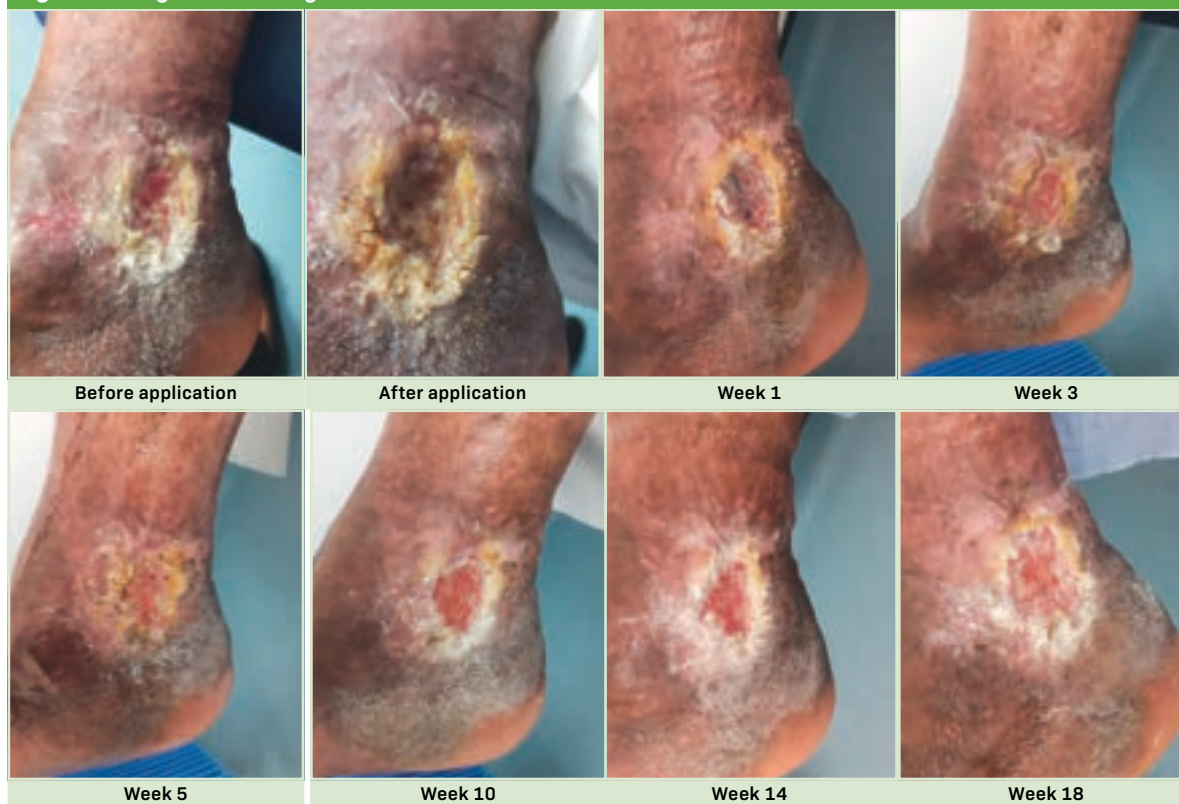Bill reported a burning sensation with a 10/10 VAS pain score during application. This was soothed by washing off and had decreased to 6/10 by 5 minutes after treatment and 4/10 at the end of the dressing change.

Follow-up

Bill was advised to continue his usual simple self-care dressing regimen between weekly clinic appointments, unless there was minimal leakage and no adverse effects, in which case he could leave his dressings intact until the next appointment. He was also advised to line the plastic bowl he used to wash his leg at home with a clean bag to minimise bacterial contamination, wash his leg in water immediately if he noticed any adverse reactions and to contact the clinic if he had any concerns.

At week 4, Bill's primary dressing was changed from the non-adherent contact layer back to zinc paste, as he found it much more soothing. Otherwise, his dressing regimen remained consistent throughout follow-up.

Bill continued to self-care between clinic visits. Healing may have been more evident if it had been possible to use compression bandaging for the entire week, as the intermittent use of wraps meant that the underlying cause was not being optimally addressed as per best practice.¹

Figure 2b. Right venous leg ulcer treated with Debrichem

Outcome

Over the 14 weeks following treatment with Debrichem, there was evidence of gradual wound progression, including autolytic debridement of devitalised tissue. This compared favourably with before treatment, when nothing seemed to shift the sloughy film, which always seemed to reform by the next appointment.

By the end of follow-up, both VLUs showed healthier, pink granulation tissue, and the wound beds were almost up to surface level, rather than shallow cavities. The wound surface area had reduced somewhat, from 4.5×2.5 cm to 3.0×2.0 cm on the right and 2.0×1.5 cm to 2.0×1.0 cm on the left leg. Meanwhile, the periwound skin was much healthier and had less build-up of dry skin, and there had been no re-infection requiring antibiotics.

These improvements were evident to Bill, and he was happy with the wound progression, although it was not rapid. Moreover, since application, he reported a complete absence of pain and malodour from the wounds, as well as reduced exudate levels, all of which improved his comfort and quality of life. This made him more positive and enthusiastic about treatment, and he felt that it may have given his hard-to-heal wounds a chance of healing without the need of vascular intervention.

Discussion

This case demonstrated that Debrichem is very easy to apply and use, and it was very satisfying to see the immediate change in appearance of the wound bed, as devitalised tissue is dry and darker in appearance.

However, the excruciating pain the patient felt while the product was on the wound bed was hard to watch, although these pain levels do begin to subside within a few minutes of cleansing. Going forward, it should be strongly recommended that patients are given analgesia, such as 5% lidocaine and prilocaine cream, before undergoing treatment with Debrichem. Likewise, clinicians need to be ready to rapidly remove the Debrichem solution immediately after the application time, which means being organised with plenty of sterile water or saline and a bowl beneath the area being treated. These associated pain levels may also make Debrichem inappropriate for use in patients with acutely infected wounds and signs of systemic infection, such as generally feeling unwell.

However, the outcome of Bill's case supports the continued use of chemical debridement with Debrichem in hard-to-heal wounds. This is especially the case where there is evident build-up of biofilm, causing recurrent localised infection requiring regular antibiotic treatment.

Case study 3. Bilateral venous leg ulceration treated with Debrichem

Priti Bhatt

Background

Clive was a 49-year-old man who had been living with intermittent venous ulceration since 2010. The ulcers affected both legs, but predominantly his left leg. Since then, he had been irregularly re-attending clinic with VLUs showing 100% thick yellow slough, high exudate levels and malodour, as well as inflammation to the periwound skin and severe wound-related pain.

At the time of presentation, Clive was working full-time as a barber and living with his partner and 9-year-old son. The pain was limiting his mobility, making his movements very slow and preventing him from walking long distances. This was difficult for someone in a profession that involves standing for most of the day, especially when he could not afford to take time off work, and it made it hard to play football in the park with his son. This was frustrating for Clive, and it resulted in low moods.

Clive had prominent varicose veins in both legs, with normal toenails, a 3-second capillary refill and no loss of sensation. He had varicose eczema in both lower legs, with dry skin, haemosiderin staining and scar tissue present. Clive's veins were likely damaged as a result of a history of intravenous drug use, for which he had been in drug-dependency treatment since 2010. These past addiction issues made him reluctant to take regular analgesia for the severe pain from his wounds. He also had a medical history of asthma, which he managed with inhalers, and he had an allergy to penicillin. In 2016 and 2017, Clive had undergone operations to place a venous stent in each leg: the first in his right leg was successful, but the second in his left leg was not.

Clive experienced repeated infections related to his VLUs, around every 3 months. In the 2 years between December 2019 and November 2021, he required eight courses of oral antibiotics, of at least 10 days.

Clive's VLUs had been washed with wound irrigation solution, antimicrobial wash lotion or antibacterial surfactant gel and mechanically debrided with monofilament pads. The wounds had then been dressed variously over the years with enzyme alginogel, honey tulle, hydrophobic microbial-binding foam, polymeric membrane, silver foam, silver Hydrofiber and silver sulfadiazine. These dressings were secured with full compression bandages or two-layer hosiery kits.

Clive generally preferred to redress his wounds himself, sometimes with full compression bandages but usually with hosiery kits. He did not like being in bandages, as they limited the types of clothing he could wear, and he did not feel comfortable wearing shorts on the beach in summertime. Clive's work and lifestyle meant that his clinic attendance was irregular and less frequent than recommended. He usually attended each fortnight or month, but he had periods of non-attendance of up to 10 months, the longest ending in October 2019, when he

presented with severe pain from an ulcer on his left inner ankle. He was also fully self-caring during the first COVID-19 lockdown between February and September 2020. The VLU in his right leg had temporarily healed in January 2021 but recurred in November 2021.

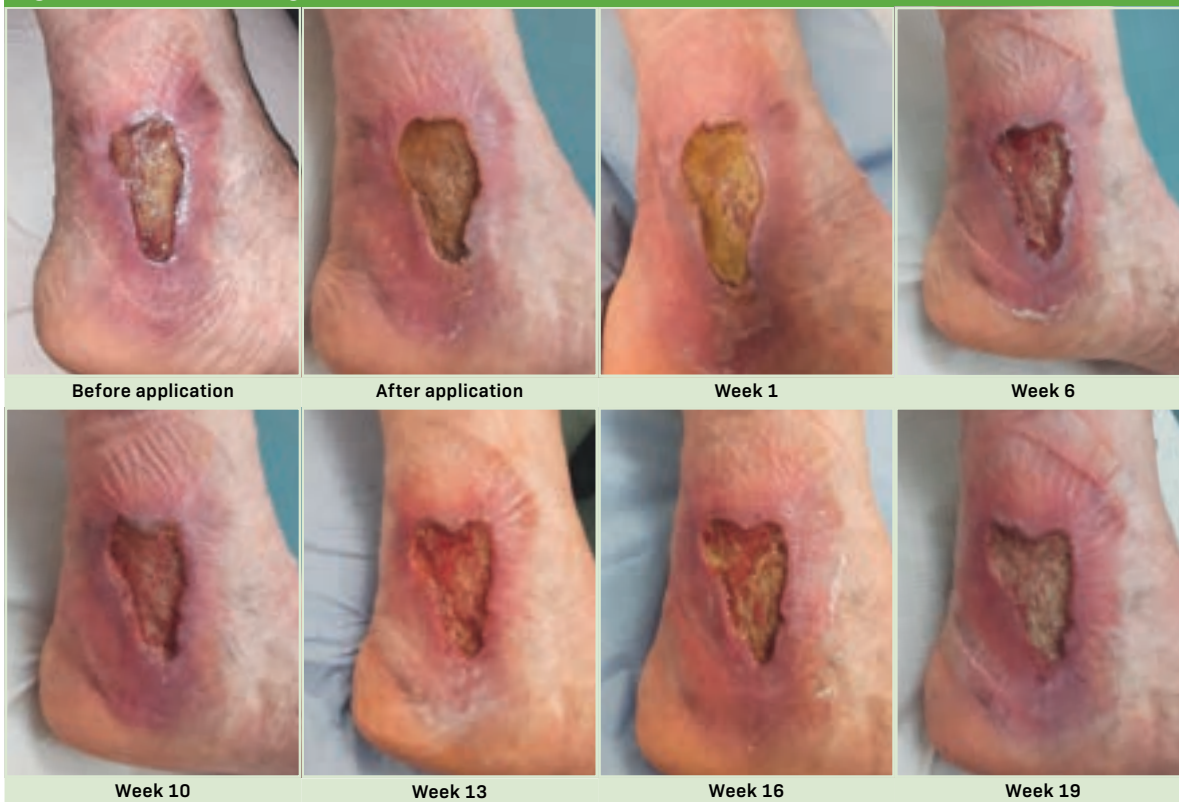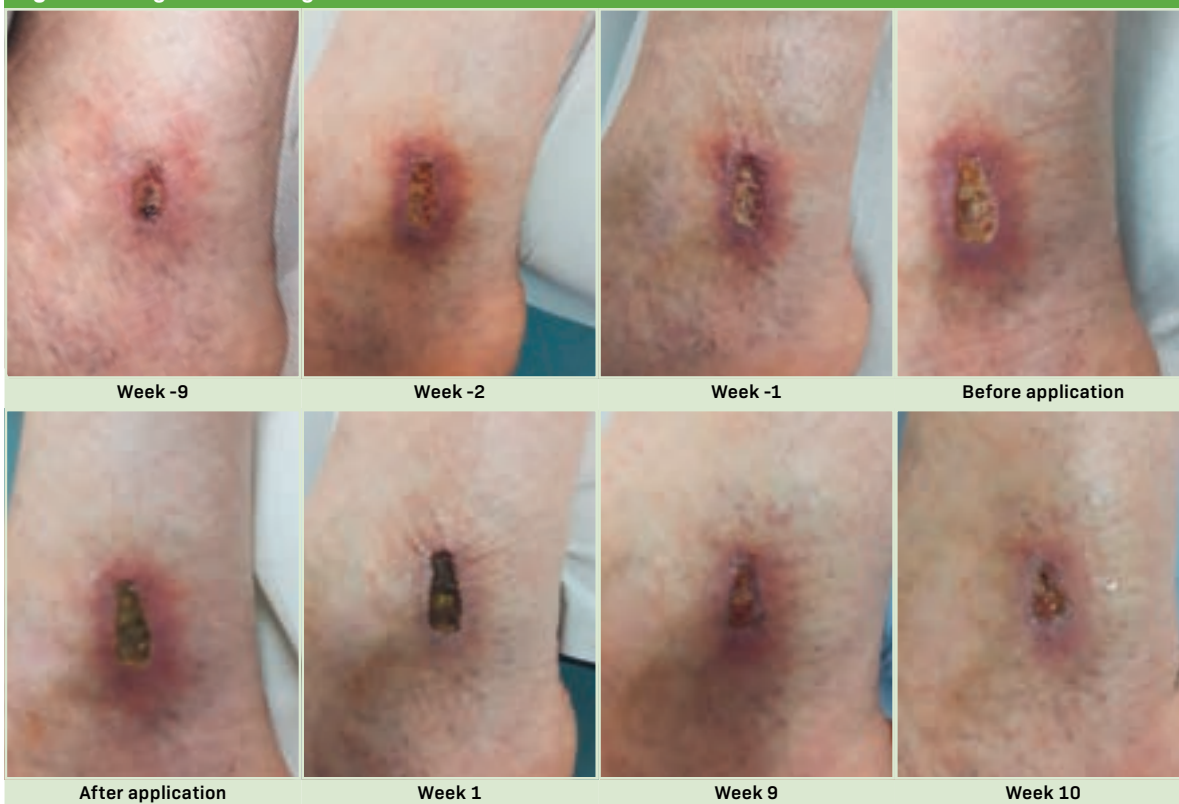
Presentation

On 25 November 2021, Clive presented at the clinic with a painful VLU on his left medial malleolus. It was evident that it had been static for some time and should be classed as a non-healing wound. This, with the 2-year history of high pain levels and repeated infection, led the clinical team to propose a trial of Debrichem.

After having the rationale and risks of the treatment explained to him, Clive was at first very apprehensive about the potential for increase in pain during the treatment, and so he did not consent right away.

Summary 3. Bilateral venous leg ulceration treated with Debrichem

Patient	49-year-old man
Medical history	Varicose veins in both legs; varicose eczema; vein damage due to intravenous drug use; asthma; penicillin allergy
Medication	Asthma inhaler, topical steroid for eczema; steroid cream, 50:50 white paraffin ointment
Wound location	Bilateral, but predominantly left medial malleolus
Wound history (time before presentation)	11 years, start of intermittent ulceration; 5 years, successful venous stent in right leg; 4 years, unsuccessful venous stent in left leg; 1 year, healing for 10 months
Holistic impacts	Pain, limited mobility, difficulty working, negative impact on family, low mood
Rationale for Debrichem	High pain, recurrent infection requiring antibiotics, no progression despite other treatments for 2 years
Regimen on presentation	Silver foam, full compression bandages or two-layer hosiery kits
Other previous treatments	Enzyme alginogel, honey tulle, hydrophobic microbial-binding foam, polymeric membrane, silver Hydrofiber, silver sulfadiazine; mechanical debridement pads
Post-Debrichem regimen	Silver foam, enzyme alginogel (after week 16), full compression bandages
Analgesia	5% lidocaine and prilocaine cream
Pain (visual analogue scale)	10/10 on presentation, 4/10 after 24 hours
Key outcomes	Slough on wound bed from 100% at presentation to 30% at week 16 and 95% at week 19 (left); wound size from 2.2×1.0 cm at presentation to healed at week 12 (right) and from 3.2×5.5 cm at presentation to 3.0×5.0 cm at week 7 (left); exudate level from high at presentation to healed at week 12 (right) and from moderate at presentation to high at week 19 (left)

Figure 3a. Left venous leg ulcer treated with Debrichem**Figure 3b. Right venous leg ulcer treated with Debrichem**

Clive presented 2 weeks later, on 9 December 2021. On review, the left ulcer (*Figure 3a*) measured 3.2×5.5 cm, and a shallow cavity was present. The wound bed was 100% covered with thick, dark yellow and well-adhered slough, and there were moderate levels of purulent dark exudate, with a slight malodour. The periwound skin was inflamed and painful to touch. Clive reported a VAS pain score of 10/10 most of the time, and he was having difficulty walking. He recognised this burning sensation from the many previous occasions when he had developed an infection and required antibiotics. Doppler assessment identified an ABPI of 0.9 on the left and 1.1 on the right leg, both within a suitable range for compression therapy. Duplex scans showed slight occlusion to vessels but that the successful venous stent had aided healing in the right leg.

Commencement

After 2 weeks of consideration, in which he talked with another patient in clinic who had experienced Debrichem application, Clive consented to having the solution used on his left VLU. He had decided that the wound pain was so debilitating that he would try anything.

Both legs were washed in a bucket of warm water and antimicrobial wash lotion before being thoroughly dried. Then, 5% lidocaine and prilocaine cream was applied to the ulcer for 10 minutes before treatment. The Debrichem solution was applied for 60 seconds, during which the patient was evidently in increased pain. After this, it was washed off with saline.

Clive's wound was redressed according to his usual care plan. A topical steroid cream was applied to eczematous areas and 50:50 white paraffin ointment to all intact skin, while the wound was dressed with silver foam and full compression bandages. He was recommended to continue this dressing routine twice a week: once at home and once when he came in for weekly reviews.

Follow-up

Within 24 hours of initial application, Clive reported a significant decrease in pain VAS score from 10/10 to 4/10. By week 7, the left VLU was shallower and slightly smaller, measuring 3×5 cm, and the wound bed appeared healthier. The dark devitalised tissue came away easily either on the dressing pad or during cleansing, and the slough was gradually replaced by healthy granulation tissue. The edges of the left VLU were granulating and red instead of purplish in colour. The slough was less viscous, and the wound bed was granulating up to the surface.

At his 7-week review, Clive reported high levels of pain, and consequent low mood, from the VLUs on both of his medial lower legs, especially the smaller ulcer on his right

leg (*Figure 3b*), which had not been treated with Debrichem. At commencement, the right VLU measured 2.2×1 cm, and there was a slight depth to centre, 100% covering of hard, dry slough on the wound bed and inflammation to the surrounding skin. Following a discussion with the clinical team, he consented to have the wound on his right leg also treated with Debrichem that day (27 January 2022). This was performed in the same way as the first application on the left leg. The only difference was that, at the patient's request, the VLU on the right leg was redressed with a two-layer hosiery kit instead of full compression bandages.

The VLU on the left leg changed little in size over 19 weeks of treatment, averaging 3.0×5.4 cm (range 2.7–3.3 cm wide and 5.0–5.5 cm long). By week 16 (31 March 2022), it showed 30% slough and inflammation to surrounding skin. By week 19 (21 April 2022), there was 95% yellow slough and increased exudate and pain, and a swab showed moderate growth of *Pseudomonas aeruginosa*. At week 16, owing to the build-up of slough in the wound, enzyme alginogel was added alongside silver foam as the primary dressing for the left VLU.

However, the VLU on the right leg showed much better progress. By week 1 (3 February 2022) it had developed a hard black scab, and by week 12 (21 April 2022) it had fully healed. After the right VLU healed, the patient continued to wear a two-layer hosiery kit on this leg to prevent recurrence.

Outcome and discussion

Clive reported that his pain related to each wound was significantly reduced after it had been treated with Debrichem. Moreover, he had since been able to walk more and for greater distances without pain, and this had enabled him to spend more time playing with his son in the park. These positive outcomes had encouraged him to request a second treatment with Debrichem to the wound on his left leg.

The VLU on the right leg fully healed within 12 weeks, whereas the left one did not. This may well be because of the much earlier commencement of Debrichem in the right ulcer, only 6 weeks after it had recurred, than in the left ulcer, when it was already a long-established non-healing wound.

Although the left ulcer had not healed by week 19, the wound did appear notably healthier after Debrichem application, and it has since granulated up towards the surface. As the level of slough had again increased, the clinical team have proposed trying a second dose of Debrichem in this wound to restart the healing process. Clive has expressed willingness, feeling it would likely be of benefit to him and preferable to using more antibiotics.

Case study 4. Venous leg ulcers on the left ankle treated with Debrichem

Priti Bhatt

Background

Dora was an 83-year-old woman with a history of intermittent bilateral venous leg ulceration, which had a significant impact on her quality of life.

Dora had a history of venous hypertension, lipodermatosclerosis, osteoarthritis, vitamin D deficiency, chronic back pain and spinal curvature. At presentation, she was taking the following medicines: aspirin, atorvastatin, furosemide, glyceryl trinitrate, irbesartan, ketoprofen, lansoprazole, lercanidipine and paracetamol.

Dora's VLUs had been treated with various dressings, including adhesive silicone dressings, antibacterial surfactant gel, enzyme alginogel, fusidic acid/betamethasone valerate, honey tulle, multi-layer

compression bandaging, non-adherent contact layer, superabsorbent pads and zinc paste. Dora could not tolerate iodine or silver dressings.

Dora's ulcers had occurred since at least 2012, but it was unclear exactly when or how they started. The initial episode of bilateral ulceration deteriorated significantly, requiring surgical debridement as an inpatient to promote healing. These earlier VLUs eventually healed in 2015, and she was discharged with compression hosiery. However, she had not been adherent to this, and this was a likely factor in the repeated recurrence of the VLUs on her left leg over the years. However, her right leg has only had one episode of recurrence, which was in 2017 and healed within 4 months, and it has since remained healed. Dora was originally prescribed class 2 compression hosiery, but she had difficulty applying it, and class 1 stockings were tried. She did not wear these daily as recommended, and, for the past 12 months, she has been wearing compression wraps on the left leg everyday instead, as these are easier to apply.

Dora's most recent episode of ulceration started in November 2016, with a small wound on her left outer ankle measuring 1.5×1.0cm. She was offered various treatments, although she refused compression bandaging due to her past adverse experience. The wound remained static in size and appearance into 2017. At that time, while under the care of podiatry, she was referred to tissue viability, as well as dermatology for assessment and management of eczematous skin on her legs.

A Doppler assessment in March 2017 revealed biphasic pulses in the left leg and triphasic pulses in the right leg, while a monofilament test yielded a score of 10/10; however, severe pain from the ulcer initially prevented a full Doppler assessment. In October 2017, an ultrasound scan of the deep veins in Dora's lower limbs found them to be generally patent and competent, although a popliteal vein was mildly incompetent and a long saphenous vein was slightly thrombosed in the left calf.

In October 2018, Dora was admitted to hospital with cellulitis and treated with intravenous antibiotics. At this time, the outer-ankle wound was covered with dry eschar, and she developed a new, larger wound on the inner left lower leg, measuring 2.5×12.0cm and 0.5cm deep. The smaller outer ankle wound temporarily healed in June 2019 but recurred in mid-2020. In May 2020, the pain had reduced just enough for Dora to tolerate a Doppler assessment, giving an ABPI of 1.08 in the left and 1.13 in the right leg, which is suitable for compression bandaging. However, it took until August 2020 for Dora to consent to this, agreeing to compression wraps between the knee and ankle only.

Presentation

By January 2022, Dora had been living with two non-healing wounds for over 3 and 5 years, respectively. For

Summary 4. Venous leg ulcers on left ankle treated with Debrichem

Patient	83-year-old woman
Medical history	Venous hypertension, lipodermatosclerosis, osteoarthritis, vitamin D deficiency, chronic back pain, spinal curvature
Medication	Aspirin, atorvastatin, furosemide, glyceryl trinitrate, irbesartan, ketoprofen, lansoprazole, lercanidipine, paracetamol; emollient gel
Wound location	Inner and outer ankle on the left leg, formerly bilateral
Wound history (time before presentation)	9 years, start of intermittent bilateral ulceration; 7 years, temporary healing with non-adherence to compression; 5 years, last ulceration on right leg for 4 months; 5 years, occurrence of presenting ulcer on left outer ankle; 3 years, occurrence of presenting ulcer on left inner ankle
Holistic impacts	Pain, exudate and malodour, social isolation, disrupted sleep
Rationale for Debrichem	High pain (causing intolerance to compression and mechanical debridement), recurrent infection requiring antibiotics, no progression despite other treatments for 5 years
Regimen on presentation	Hydrogel, compression wraps
Other previous treatments	Adhesive silicone dressings, antibacterial surfactant gel, enzyme alginogel, fusidic acid/betamethasone valerate, honey tulle, multi-layer compression bandaging, superabsorbent pads and zinc paste (intolerant of iodine or silver dressings)
Post-Debrichem regimen	Non-adherent contact layer, superabsorbent pad, elasticated viscose stockinette, compression wraps
Analgesia	Oral morphine; 5% lidocaine and prilocaine cream
Pain (visual analogue scale)	8–10/10 on presentation, 10/10 during application, 8/10 by bedtime, ~4/10 through follow-up
Key outcomes	Slough on wound bed from 100% at presentation to 60% at week 4 and 5% at week 14 (outer) and from 100% at presentation to 90% at week 4 and 10% at week 14 (inner)

the 2 years, she had been living with constant severe pain, with VAS pain scores of 8–10/10. In this time, she also had recurrent cycles of cellulitis and wound infections every 2–3 months, which required regular antibiotics, causing abdominal discomfort. Moreover, the pain, exudate and malodour made her unwilling to leave her home and socialise, which she used to do using a rollator frame or wheelchair. Although she could independently move around her upstairs maisonette, she was very lonely with just her budgie for company. She had a very supportive daughter living nearby, but she had health issues of her own.

In light of all this, the clinical team proposed trialling Debrichem. It was hoped that this would reduce Dora's pain enough for her to reconsider compression bandaging, which was essential to address the underlying cause of the wounds. Debrichem was also expected to reduce the bacterial burden of the wound and surrounding skin, breaking the cycle of antibiotics. All this was explained to her, including the high localised pain that would be briefly felt during the one-off treatment, with reassurance that analgesia would be used to reduce this. However, at that point, Dora felt she would try anything, as she was not getting much sleep. Following several discussions with the clinical team, Dora consented to trial Debrichem on 25 January 2022.

On presentation that day, the small VLU on the left outer ankle (*Figure 4a*) and the large VLU on the inner lower leg (*Figure 4b*) both had a consistent yellow slimy covering of slough, which could not be removed with a debridement pad (which Dora found uncomfortable).

They were being dressed with hydrogel, as she had been unable to tolerate many other dressings. The surrounding skin was very dry and irritated, requiring treatment with a steroid cream.

Commencement

On 25 January 2022, Dora was advised to take the oral morphine 30 minutes before the treatment visit. Her left leg was washed as normal with warm water and an antimicrobial lotion in a bowl lined with a clean bag and then dried. After this, 5% lidocaine and prilocaine cream was applied to the wounds and surrounding skin for 15 minutes and then washed off with water. Next, Debrichem was applied to both wounds using a gloved finger to distribute the solution over the entire wound bed and edges as quickly as possible, as per manufacturer instructions. It was left in place for 60 seconds before being rapidly irrigated with at least 1 litre of sterile water. The wound bed was seen to have turned a very dark colour.

Afterwards, as per Dora's normal care plan, the rest of the flaky skin on her leg was thoroughly dried and moisturised with emollient gel. Then, the wounds were dressed with a non-adherent wound contact layer and a superabsorbent pad and secured with an elasticated viscose stockinette and compression wraps applied from the ankle to below the knee.

Dora reported excruciating 10/10 pain during application. This continued during irrigation and settled only slightly once the dressing change was completed. The pain level had eased to 8/10 by bedtime after she had taken paracetamol.

Figure 4a. Venous leg ulcer on the left outer ankle treated with Debrichem

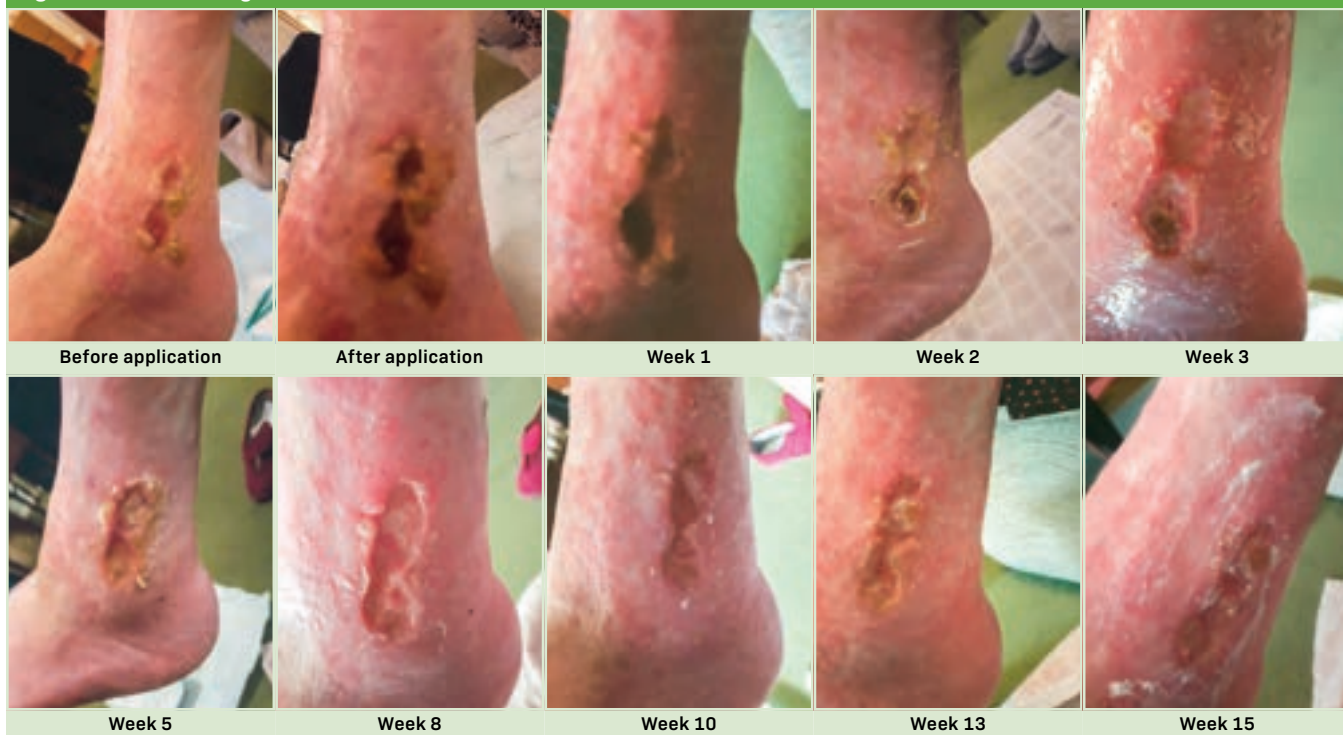
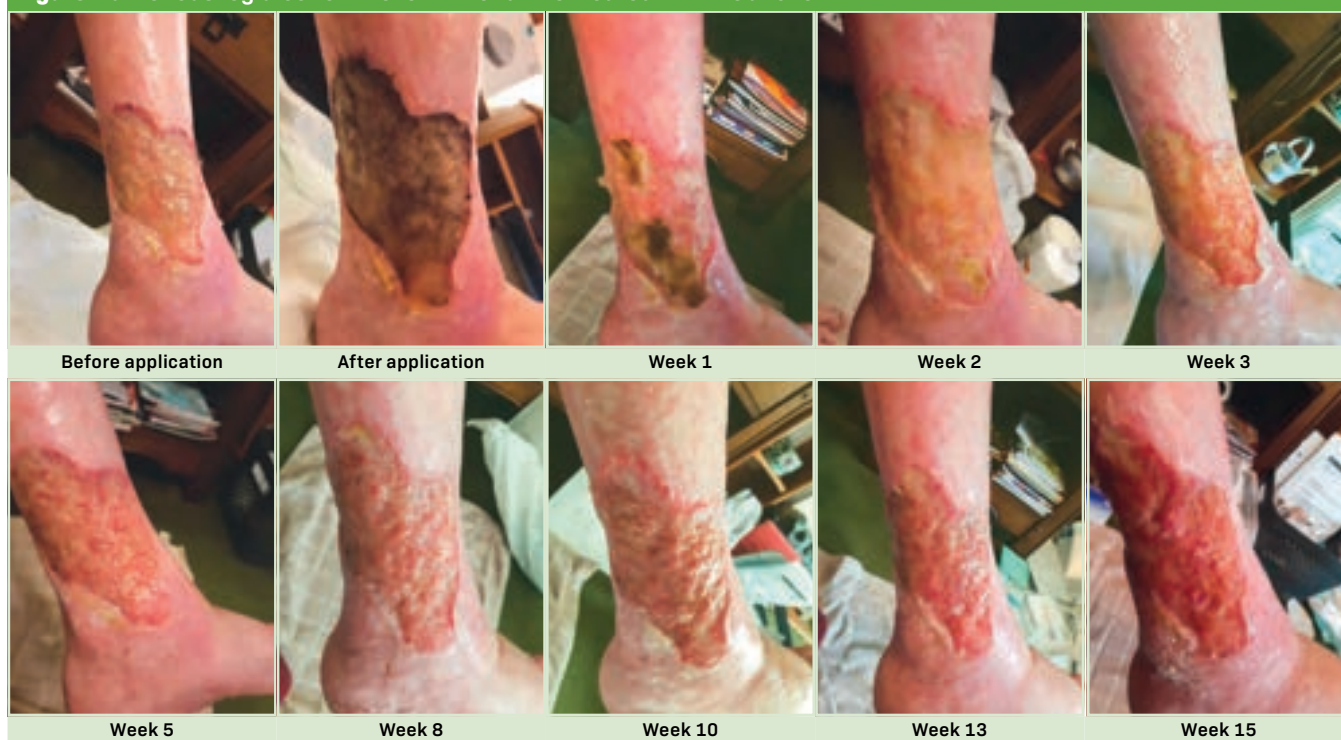


Figure 4b. Venous leg ulcer on the left inner ankle treated with Debrichem

Follow-up

In the large VLU on the inner lower leg, the thick, dry and crusty devitalised plaques of tissue (a common area for harbouring bacteria) were removed during washing on week 2, leaving the wound bed showing 100% non-shiny thin yellow slough. Starting from the wound edges, this was gradually replaced by healthy pink granulation tissue, which covered 10% by week 4, 20% by week 6, 60% by week 8, 80% by week 10 and 90% by week 14. The wound bed was almost completely up to surface level by week 6 and fully up to the surface by week 12. By week 8, the surrounding skin was pink and healthy. At week 12, maceration was noted at the lower end of the wound, probably due to previously missed dressing changes while the patient had been unwell.

At week 2, the small VLU on the outer ankle had a wound bed comprising 20% thick necrotic tissue, 60% yellow slough and 20% healthy pink granulation tissue, with dry edges and a shallow cavity. At week 4, the necrotic tissue was removed during washing, leaving slough beneath. The coverage of granulation tissue increased to 85% at week 6, 90% at week 8 and 95% at week 14. At week 16, the wound bed comprised 5% slough, 85% granulation tissue and 10% epithelial tissue. At week 6, the hard dry skin on the wound edges began to loosen and lift, making the wound appear slightly larger. The wound depth was seen to have decreased at weeks 8 and 12.

Through follow-up, the wounds produced a moderate amount of serosanguinous exudate level, which up to week 6 was mainly from the VLU on the inner lower leg.

After reporting night-time VAS pain scores of 8/10 on week 2, in the following 14 weeks, Dora's reported VAS scores were greatly reduced, generally down to 4/10 and reaching only 6/10 at worst during dressing changes. This has led to a great improvement in her mood, sleep and overall quality of life. Moreover, there have been no further infections in this time, so Dora has not required any antibiotics, thus avoiding abdominal discomfort and improving her nutritional intake.

Her care plan has remained steady, with the addition of tubular bandages. After 1 week, there was an obvious thick layer of devitalised tissue debriding from the wound bed. From week 2 to week 15, the wound beds showed healthier-looking granulation tissue, with minimal thin yellow slough in small areas, and gradually epithelialised upwards to surface level.

Discussion

Dora was disappointed that her wounds had not completely healed, and so it was reiterated to her that they would not heal without addressing the underlying cause. At week 12, she consented to trying two-layer compression bandaging for the first time in years. However, by the next review at week 14, she elected not to continue with them, despite evident improvement in her wounds over this time. However, Dora has since agreed to try a two-piece class 1 compression hosiery system beneath her compression wraps, which will at least provide increased light compression from her toes to below the knee. The aim is to hopefully step up the class of compression once Dora has become used to the

new regimen and can see the improvement for herself. In Dora's case, use of Debrichem appears to have achieved the aims of reducing pain and bacterial load and

increasing patient concordance and quality of life. By doing this, it is also likely to have contributed to a cost saving for the NHS.

Case study 5. Three venous leg ulcers on the right leg treated with Debrichem

Emma Bennett, Sarah Molden and Katie Leek

Background

A 65-year-old male patient, Elliot, first presented to primary care in March 2021 with itching on his right lateral leg that had developed into venous leg ulceration. Elliot reported that the ulcer was causing wound pain VAS scores of between 7 and 10/10. He had a medical history of hypertension and total right hip replacement. His body mass index was in normal limits, and he smoked around 20 cigarettes a day.

Elliot was seen by his GP and district nursing team, who completed an ABPI (with results within normal limits) and recommended strong compression therapy. This compression caused Elliot pain and tenderness, and so he was not always adherent to the plan of care. He was initially commenced on co-codamol for pain. Later, he was also prescribed morphine and pregabalin and then buprenorphine patches by his GP. Between December 2021 and March 2022, he was prescribed four courses of antibiotic treatment with flucloxacillin for *Streptococcus* group C and *Staphylococcus aureus* infections.

In January 2022, he was referred by his GP to a dermatology team, as the ulcer had been present for 9 months. The dermatology team undertook a punch biopsy, which came back negative. In March 2022, Elliot was referred to the vascular team, in line with local Commissioning for Quality and Innovation scheme guidance. The vascular team identified large varicosities in the thigh and venous symptoms (haemosiderin staining and ankle flare) in his right leg. His foot was warm and pink, and the capillary refill was less than 2 seconds. An ultrasound scan confirmed considerable reflux of the superficial venous system. He was recommended to undergo surgery, involving high tie, ligation stripping and avulsion of varicose veins, followed by compression therapy.

Elliot underwent this surgery on 12 April 2022. Following this, the wound pain VAS score remained at 7–10/10, despite analgesia with co-codamol, pregabalin and buprenorphine patches. The pain was affecting his mobility and his ability to sleep, and he was low in mood. The exudate levels had been moderate to high during this time.

Elliot continued to attend follow-up assessments with the vascular nurse, who recommended antimicrobial dressings for local bacterial colonisation. An enzyme alginogel was used to facilitate autolytic debridement. This was covered with an absorbent pad and secured in place with a British standard compression liner at the ankle. The vascular nurse had recommended at least 20 mmHg of compression, but Elliot had not been able to

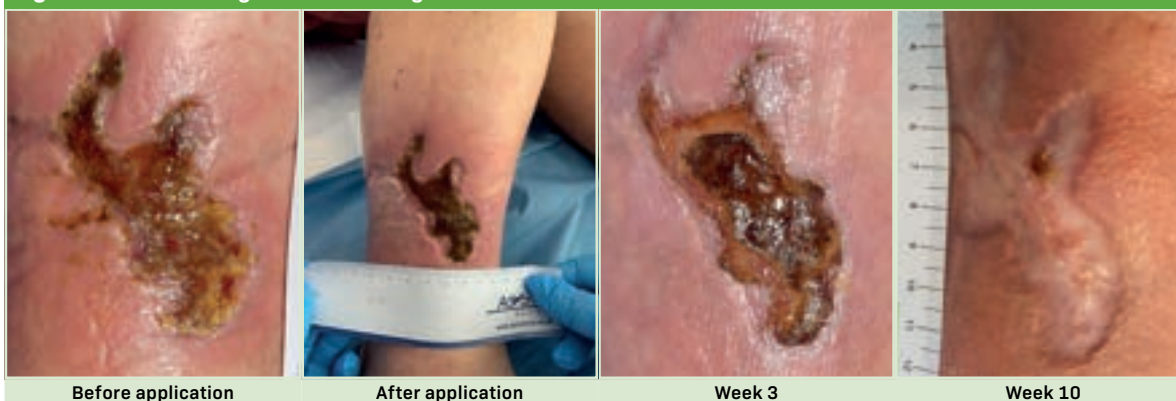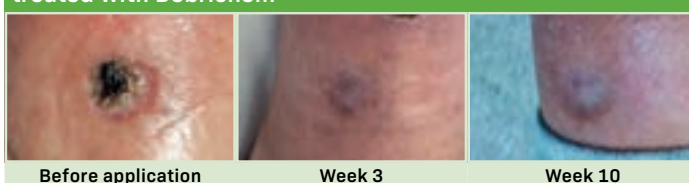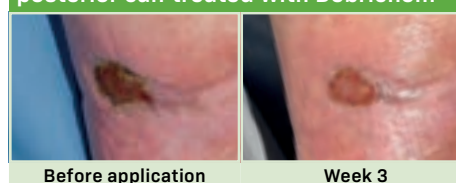
tolerate this due to pain and could only manage 10 mmHg. He was not always able to tolerate this either and would sometimes remove the liner. Recognising that Elliot's wound was not improving, the vascular nurse brought him to the attention of the tissue viability team.

Presentation

On 25 May 2022, the tissue viability and vascular nurse teams completed a joint assessment. On examination, there were three wounds: on the anterior shin, on the lower anterior shin and on the posterior calf. The anterior shin wound measured 3.0×6.5 cm and comprised 70%

Summary 5. Venous leg ulcers on the right leg treated with Debrichem

Patient	65-year-old man
Medical history	Hypertension, total right hip replacement
Medication	Co-codamol, morphine, pregabalin, buprenorphine patches
Wound location	Right lateral leg
Wound history (time before presentation)	14 months, diagnosis of ulceration; 6 weeks, high tie, ligation stripping and avulsion of varicose veins, followed by compression
Holistic impacts	Reduced mobility, disrupted sleep, low mood
Rationale for Debrichem	Pain (causing intolerance to mechanical debridement); unsuitability for sharp debridement; no progression despite other treatments for 15 months
Regimen on presentation	Enzyme alginogel, absorbent pads, British standard compression liners (10 mmHg)
Other previous treatments	Antimicrobials, surgical intervention
Post-Debrichem regimen	Low-adherent polyester mesh dressing, absorbent pads, British standard compression liners (20 mmHg)
Analgesia	5% lidocaine and prilocaine cream
Pain (visual analogue scale)	7–10/10 up to presentation, 6/10 before application, 10/10 during application, 6/10 after 5 minutes, 3/10 during debridement and cleansing, 0–4/10 through follow-up
Key outcomes	Slough on wound bed from 70% at presentation to 20% at week 3 and healed at week 10 (anterior shin) and from 20% at presentation to 10% at week 3 and healed at week 10 (posterior calf); wound size at presentation from 3.0×6.5 cm to 2.5×6.0 cm (anterior shin), 1.0×1.0 cm to healed (lower anterior shin) and 2.6×1.7 cm to 2.0×1.0 cm (posterior calf) at week 3; exudate level from moderate at presentation to minimal at week 3

Figure 5a. Venous leg ulcer on the right anterior shin treated with Debrichem**Figure 5b. Venous leg ulcer on the right low anterior shin treated with Debrichem****Figure 5c. Venous leg ulcer on the right posterior calf treated with Debrichem**

slough and 30% granulation tissue (*Figure 5a*). The lower anterior shin wound measured 1.0×1.0 cm and comprised 100% dry eschar (*Figure 5b*). The posterior calf wound measured 2.6×1.7 cm and comprised 80% granulation and 20% slough (*Figure 5c*). The wound edges were dry and chronic, and there was localised erythema, which was blanching. Meanwhile, the wound was producing a moderate volume of non-malodorous serous exudate. At the time, Elliot's wound pain VAS score was 7/10, but it had been as high as 10/10 at times over the preceding months.

Commencement

Elliot's wounds had been static and non-healing for 15 months, despite multiple courses of antibiotics and antimicrobials, as well as surgical intervention and an attempt at some level of compression, although at subtherapeutic levels. Therefore, it was decided that Elliot could benefit from active debridement. He had been unable to tolerate mechanical debridement, and the wound beds were not suitable for sharp debridement, and so it was decided to try Debrichem.

Elliot was fully informed about the product, its mechanism of action as an acidic dehydrating gel and its possible side effects, and he happily consented to try it. In view of the high pain levels he had endured to date, a local anaesthetic (lidocaine and prilocaine) was used to ease pain during application. The acidic dehydration gel was applied in accordance with the manufacturer's guidance, which included ensuring the wound edges were coated. The gel took 10 minutes to apply. Following treatment with the acidic dehydration gel, the wound was cleansed with

saline and debrided with a monofilament pad. After this, a plain low-adherent polyester mesh dressing with an absorbent pad was secured in place at the ankle with two British standard compression liners (providing 20 mmHg of pressure in total). The treatment plan was communicated to the district nurse hub and community tissue viability team.

Elliot reported a wound pain VAS score of 6/10 before application. During application, this increased to 10/10, despite the anaesthetic; he described it as an intense burning pain that was most painful on the surrounding intact skin. Elliot was given the opportunity for the Debrichem to be removed immediately, but he advised that the pain, although 10/10, was tolerable. Then, 5 minutes after the procedure, the VAS score had reduced back to 6/10. During cleansing and debridement, Elliot only experienced mild pain (3/10).

Follow-up

On 15 June 2022, Elliot went for a 3-week follow-up appointment with the tissue viability and vascular nurse teams. There, he reported that his wound pain VAS score in the intervening period was only 4/10 at worst, and at times he had been pain free. On examination, the anterior shin wound had reduced in size to 2.5×6.0 cm, appeared more superficial and comprised 70% dry granulation tissue, 20% wet slough and 10% epithelial tissue. The lower anterior shin wound had healed. The posterior calf wound had reduced to 2.0×1.0 cm and comprised 50% wet epithelial tissue, 40% granulation tissue and 10% superficial slough. There was minimal exudate, no malodour and no clinical signs of infection, and the

localised erythema observed at the initial assessment had resolved.

For the past 3 weeks, Elliot had continued using buprenorphine patches but felt less reliant on them. He had been able to tolerate the two liners most of the time, only on occasions reducing to a single and not needing to remove them completely. He had experienced a medical adhesive-related injury (MARSI) on removal of a surgical adhesive dressing, which had been used instead of a low-adherent polyester mesh dressing, against advice from the acute tissue viability team to the community tissue viability and district nursing teams. The district nursing team had also not been using the monofilament debridement pad.

Elliot's wounds were cleansed with saline and debrided with a monofilament pad, during which he reported a wound pain VAS score of 3/10, but this quickly resolved. With district nurse support, the wounds were redressed according to the same management plan, using a low-adherent polyester mesh dressing, an absorbent pad and two British standard compression liners.

On 2 August 2022, Elliot attended a routine follow-up appointment with the vascular consultant and tissue viability nurse. On examination, all three wounds appeared to have healed, including the MARSI, and all areas had 100% epithelialised, although they remained fragile. Elliot reported noticing that they had healed on 22 September 2022, and he had since continued to wear the double compression liners. The tissue viability team encouraged Elliot to continue to wear these compression liners and to apply a moisturiser daily to maintain skin integrity. He was signposted to his GP for 6-monthly repeat prescriptions of the hosiery and emollient. The consultant and tissue viability team were pleased with the outcome and discharged Elliot from both services.

Discussion

In this case, the tissue viability and vascular nurse teams had made the decision to use Debrichem due to Elliot's long-term experience of a non-healing wound that caused continuous high levels of pain and severely affected his quality of life. This also caused him to need repeated courses of antibiotics, which were increasing his risk of antimicrobial resistance. Surgical intervention had improved the pain only slightly, and the wound remained non-healing. Elliot showed signs of venous disease, but he had been unable to consistently tolerate the strong therapeutic levels of compression advocated to aid healing, even after surgery. Therefore, it was felt that use of chemical debridement with Debrichem might break the cycle of non-healing, pain and antibiotics.

This seemed to be the case. After application of Debrichem, Elliot reported that his wound pain had reduced, in turn increasing his mobility, allowing him to tolerate the compression liners and significantly improving his quality of life. He was relieved that he had not required any further courses of antibiotics and was ecstatic that the wound had finally healed.

It should be acknowledged that improvements observed in Elliot's wound may have resulted from earlier interventions, such as the vascular surgery or reduced compression therapy. However, this is less likely, as he was not able to tolerate therapeutic levels of compression at any stage before healing. Only after Debrichem application did his pain reduce and he became able to tolerate reduced compression. The most likely explanation available is that the application of an acidic dehydration gel helped disrupt the chronic inflammatory stage of healing and kickstart processes of autolytic debridement and granulation.

Case study 6. Venous leg ulcer with atrophie blanche treated with Debrichem

Hayley Turner-Dobbin

Background

Gladys was a 76-year-old woman with a long-term history of recurrent venous leg ulceration. Gladys first developed VLUs in 2005. These VLUs were slow to heal and affected her quality of life, causing pain and stress related to having to attend appointments, as well as limiting her preferred activities, such as going on cruises.

She also had a medical history of osteopenia, iron deficiency, varicose eczema and varicose veins, for which she had undergone varicose vein stripping in 1982. She was not taking any medication, except for paracetamol as needed for the wound-related pain.

Gladys's VLUs were managed with compression therapy using full compression bandages. They had also previously been mechanically debrided with debridement pad or wipes and variously dressed with antimicrobials, non-contact dressings and superabsorbent pads, depending on the exudate level and presence of infection.

When Gladys had a VLU, she was always fully engaged with all recommended treatment and she attended all clinical appointments. This had repeatedly resulted in temporary healing, after which she would be discharged with advice to self-manage with compression hosiery. However, since then, the VLUs had recurred at least four more times. These recurrences involved high levels of pain, which was thought to generally be due to the presence of atrophie blanche, a pattern of scarring that can develop from healed ulcers of the lower leg, ankle or dorsal foot (livedoid vasculopathy). It appears as white atrophic stellate scars with peripheral telangiectasias, and it is believed to involve occlusion of the blood vessels in the superficial dermis with subsequent skin ulceration.²

Full compression bandages needed to be selected carefully for Gladys, because she had small, thin legs that presented a professional challenge. Her 17 cm ankle

Summary 6. Venous leg ulcer, atrophie blanche treated with Debrichem

Patient	76-year-old woman
Medical history	Osteopenia, iron deficiency, eczema, varicose veins
Medication	Paracetamol as needed
Wound location	Lower leg
Wound history (time before presentation)	17 years, start of recurrent ulceration; 7 weeks, occurrence of presenting wound
Holistic impacts	High pain (from atrophie blanche), anxiety, limited leisure activities
Rationale for Debrichem	Increasing size and slough despite treatment; previous debridement options had not been effective in the long term
Regimen on presentation	Wadding/padding, compression bandages (two-layer or short-stretch, depending on pain)
Other previous treatments	Mechanical debridement pads, various antimicrobial dressings, non-contact dressings, superabsorbent pads; (when discharged) class 2 compression hosiery
Post-Debrichem regimen	Simple adherent dressing, two-component compression bandage kit
Analgesia	Paracetamol but no topical anaesthetic
Pain (visual analogue scale)	0/10 before application, 100/10 during application, 5/10 after application, 3/10 at weeks 1 and 6
Key outcomes	Slough on wound bed from 72% at presentation to 100% at week 1 and 29% at week 4; wound size from 3.8×7.0cm at presentation to 3.6×5.8cm at week 3

circumference was smaller than the average 18–25cm range for which most compression bandage kits are developed and, thus, classed as vulnerable. This is an important safety consideration, as the ankle circumference influences the sub-bandage pressure, which is increased in a smaller circumference. Therefore, before bandaging, wadding/padding was applied to her ankle to increase the circumference to at least 18cm, reshape it to ensure a conical graduation up the leg and protect vulnerable areas or bony prominences.³

When discharged, Gladys used class 2 compression hosiery with or without a compression wrap, and she tried both flat knit and circular knit (although at times she could only tolerate circular knit due to pain). However, she was not always consistent in regularly renewing her hosiery, resulting in loss of firmness and compression strength and likely contributing to the regular recurrences. The reasons for this are unclear but may be due to increased caring responsibilities for her son, who has learning and mental health disabilities, causing her to deprioritise her own needs.

Presentation

Gladys presented immediately following the most recent recurrence of ulceration, which began in September 2022 after 5 months of healing and involved highly painful atrophie blanche. The VLU was dressed with either

two-layer or short-stretch compression bandages, depending on pain levels.

By 20 October 2022, after 4 weeks, the wound area was 18.9cm²—3.8cm at the longest point and 7cm at the widest (*Figure 6*). The wound bed was covered with 72% yellow slough and 28% healthy granulation tissue, with advancing epithelialising edges. There was moderate moisture or serous exudate, requiring twice weekly dressing changes. The surrounding skin was healthy, with some dry scales of hyperkeratosis. A swab suggested that infection was not present.

It was evident that current treatment was not working, and the wound was deteriorating, increasing in size and becoming more sloughy. Previous debridement options had not been effective in the long term. Therefore, it was decided to offer use of a new option for chemical debridement, Debrichem, to remove devitalised tissue to encourage granulation tissue formation and wound healing.

Commencement

On 20 October 2022, Gladys was informed about Debrichem, given an information booklet and encouraged to ask questions. She gave her written and verbal consent for treatment that day.

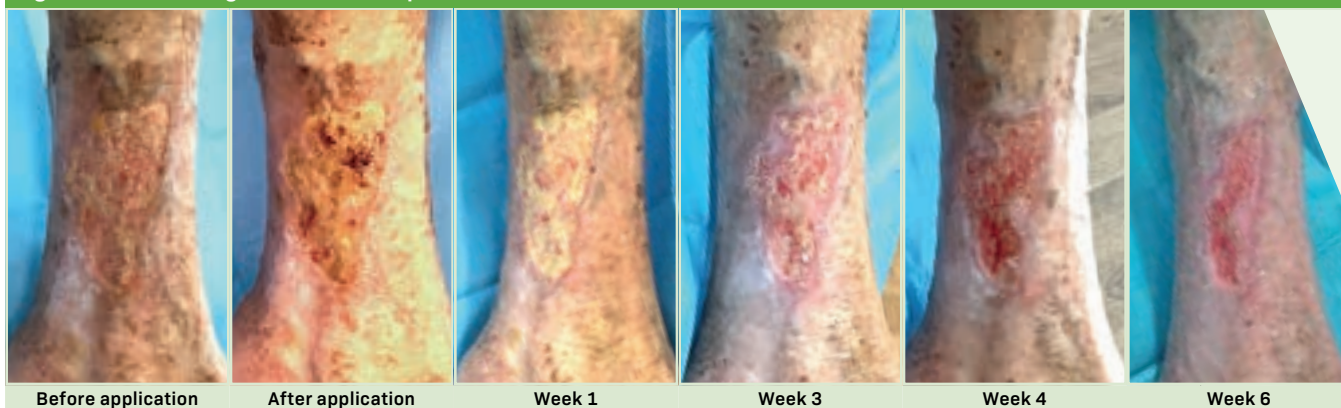Gladys took paracetamol, but no topical anaesthetic was used. Debrichem was applied according to the manufacturer's instructions and rinsed off with normal saline irrigating solution. Afterwards, the wound was dressed with a simple adherent dressing and a two-component compression bandage kit.

Before application, Gladys reported a wound pain VAS score of 0/10. While Debrichem was in situ, she briefly experienced extreme pain, describing it as 100/10 on a 0–10 scale where 10 is the worst pain possible, and she had felt unable to speak due to the amount of pain. She was only able to tolerate the application for up to 40 seconds, rather than the recommended 60 seconds. However, immediately after application, her wound pain VAS score fell to 5/10. Moreover, after the appointment, she stated that she would consent to having a Debrichem application again if it would promote healing, because the pain, although very high, was only experienced briefly during application.

Follow-up

At the first follow-up assessment 1 week later, the wound area had reduced to 17.1cm² (4.7cm long by 6.8cm wide). The wound bed comprised 100% slough, which may have been a consequence of Debrichem application, and the wound was producing a moderate volume of serous exudate, requiring twice-weekly dressing changes. Gladys reported a wound pain VAS score of 3/10, which was a slight increase from the 0/10 before application. The reason for this was not clear but might have been due to the atrophie blanche causing occlusion of small blood vessels in the middle and deep dermis, which can be painful and prevent normal healing.²

By week 3, the wound area had reduced to 10.7cm² (3.6cm long by 5.8cm wide). The wound bed comprised

Figure 6. Venous leg ulcer with atrophie blanche treated with Debrichem

70% slough and 30% granulation tissue, which was an improvement from week 1 and similar to presentation. Gladys was inconsistent in describing the pain, saying that it did not hurt but then giving a slightly increased wound pain VAS score of 4/10, and she was visibly in pain during cleansing. It was unclear if she had difficulties in articulating her health needs.

By week 4, the wound bed comprised only 29% slough, which was a notable decrease from presentation.

By week 6, the wound area had decreased again, although no measurements were recorded at this point. There was epithelial tissue on its edges, and Gladys's wound pain VAS score had fallen to 3/10.

Discussion

Overall, Gladys's wound showed good improvement, with decreasing size, epithelialisation and contracting edges.

However, this case underlined the need to mitigate the extreme pain experienced during application for any future use of Debrichem. Gladys was one of the first patients on the wound caseload, and she was not given a topical anaesthetic. In all the team's subsequent trials of Debrichem, patients have been offered an anaesthetic cream. This has minimised their pain experiences and allowed them to tolerate application for the full 60 seconds recommended by the manufacturer, potentially making the therapy much more effective.

Another observation was that use of a gloved hand to apply Debrichem could be making them anxious, as they do not like to see hands in wounds. This could make them pre-empt pain, possibly increasing their overall perception of pain. This could potentially be avoided with the availability of an applicator, which could also make it easier to control where the solution is applied.

Case study 7. Mixed-aetiology leg ulcer treated with Debrichem

Annabelle Mooney

Background

Freddy was a 49-year-old man with a 12-year history of continuous ulceration on the right leg. This large, circumferential non-healing wound was malodorous and sloughy. He experienced local infection leading to a regular recurrence of systemic infection around four times a year, which required a combination of topical antimicrobials and oral antibiotics.

Freddy's medical history included anaemia, epilepsy and obesity. His body mass index (BMI) had increased to 53.38 by the time of this case study, and he felt that this was a result of poor diet and overeating due to low mood related to his wound. He was an ex-smoker, and he did not have neuropathy. He had a stoma. In 1995, he had had a below-knee amputation in the left leg following a deep vein thrombosis. He lived alone, and he struggled to mobilise around his home and make his own meals. He slept in an upright position in a chair, day or night.

Initially, Freddy was under the care of the leg ulcer clinic, who treated him with a care plan including long-stretch bandages for compression. However, this did not control the underlying oedema or promote wound healing, and his wound remained sloughy and prone to infection, and so, after 8 years, Freddy was referred to vascular services. A toe brachial pressure index (TBPI) suggested a mixed aetiology, with a largely venous component and some arterial components, and a positive Stemmer sign confirmed lymphoedema (although the ulceration meant that the lymphoedema service was not involved). For the next 5 years, his lympho-venous disease was managed using four-layer compression bandaging, although he struggled with the heavy bandaging.

On 3 February 2021, Freddy was assessed by the community tissue viability nursing team, who continued to provide regular input. Following this, his wound was managed with antimicrobial dressing (silver Hydrofibre

Summary 7. Mixed-aetiology leg ulcer treated with Debrichem	
Patient	49-year-old man
Medical history	Anaemia, epilepsy, obesity, ostomy, below-knee amputation of left leg following DVT
Medication	None stated
Wound location	Right leg
Wound history (time before presentation)	12 years, start of continuous ulceration; 4 years, referral to vascular services and diagnosis of lympho-venous disease; 11 months, start of regimen
Holistic impacts	Reduced mobility, pain
Rationale for Debrichem	Recurrent infection, no progression despite other treatments for 12 years
Regimen on presentation	Silver Hydrofibre, cadexomer iodine pads; short-stretch double-layer compression bandages (40 mmHg); sharp debridement, three times per week
Other previous treatments	Long-stretch four-layer compression bandages
Post-Debrichem regimen	Silver Hydrofibre, cadexomer iodine pads; short-stretch double-layer compression bandages (40 mmHg); mechanical debridement, three times per week; sharp debridement monthly
Analgesia	5% lidocaine and prilocaine cream
Pain (visual analogue scale)	4–6/10 on presentation, 0/10 during application, 8/10 on day 4 with sepsis, 3/10 at week 16
Key outcomes	Slough on wound bed from 100% at presentation to 100% at week 16 after first application and to 60% at week 4 after second application; wound size from 17.0×19.0 cm at presentation to 15.0×20.0 cm at week 16 after first application to 11.1×11.8 cm at week 4 after second application; exudate level from high at presentation to moderate at week 16 after first application to low at week 4 after second application

and cadexomer iodine pads) and compression therapy to reduce slough and the chance of systemic infection. Due to Freddy's large limb circumference, he was recommended to change his familiar four-layer compression bandaging to short-stretch toe-to-knee

inelastic compression bandaging (starting at 10×6 cm, 40 mmHg double-layer). After much discussion, he agreed to this. Due to high levels of recalcitrant slough and exudate, the dressings were changed three times per week. This management routine represented a high cost to the NHS in terms of wound care products and nursing time.³

From February 2021, mechanical debridement was performed three times a week by the district nurse and sharp debridement monthly by a tissue viability nurse; however, this was not effective, as the wound would often be again covered in thick slough by the next visit. At the same time, nutritional support was provided as adjunct management to optimise his condition and in turn improve wound healing.

Presentation

In December 2021, Freddy was admitted to hospital with cellulitis, where he was seen by the tissue viability nurse.

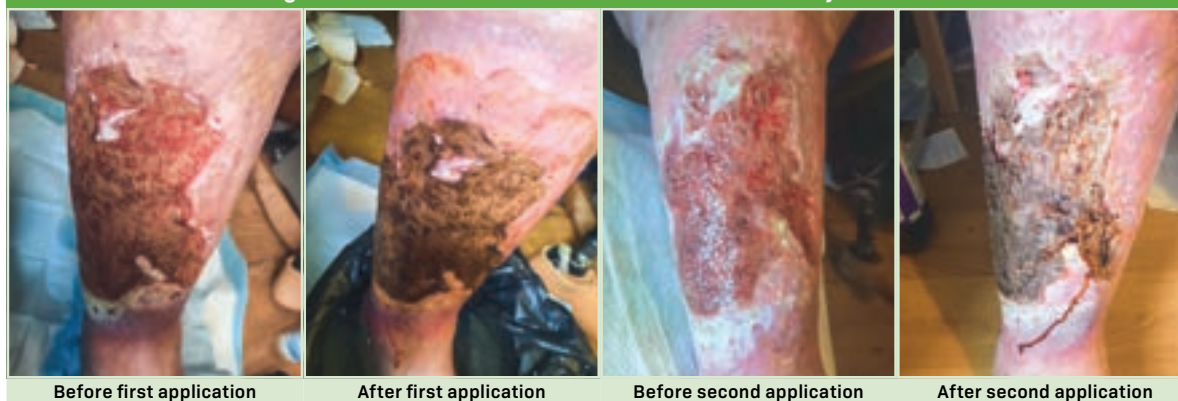On presentation, the large ulcer on his right leg measured 17×19 cm, with a depth of 0.5 cm (*Figure 7*). The wound bed was fully covered with a very thick layer of viscous slough, which was raised above the level of the wound edge margin. It was producing a high level of thick malodorous exudate. There was maceration and excoriation of the periwound skin at the lower end of the wound. Freddy was experiencing moderate amount of wound pain, with a VAS score of 4–6/10.

Commencement

Freddy's wound was evidently hard-to-heal, with 4-weekly photographs and measurements showing static margins and no signs of improvement. It was thought that this delaying healing was likely because the wound had been colonised with biofilm, and this could be tackled with debridement. As mechanical debridement had proved ineffective, it was decided to apply a new one-off chemical debridement option, Debrichem, to remove bacteria from the wound bed and stop the re-infection cycle.

On 23 December 2021, Freddy gave his consent for the treatment. He took an active interest in his lower limb

Figure 7. Mixed-aetiology leg ulcer before and after two treatments with Debrichem, showing slough and necrotic tissue darkening as it is solidified and lifted off the wound bed by the desiccant action



care journey and was keen to be involved and try new treatments.

That day, a local anaesthetic (5% lidocaine and prilocaine) was applied to limit potential pain during application.

Following the instructions, the Debrichem vial was first shaken to activate the semi-acidic gel by kinetic energy. It was then poured directly onto the wound and, using a pair of surgical gloves, spread all over the wound bed and 1cm into the periwound area (which often harbours biofilm and can be missed with sharp debridement). Some pressure was applied to ensure it penetrated the wound bed. Once spread, the Debrichem was left on the wound for 60 seconds, after which it was thoroughly rinsed off with 1 litre of saline, dried and dressed. According to the manufacturer, empty Debrichem glass vial can be washed out and recycled, while new vials have a 3-year shelf life and can be stored ambiently, which is convenient.

Freddy did not feel any pain during application, reporting only a sense of warmth and that it smelled like beetroot as it was carbonising. Immediately after, the wound tissue was visibly dried out and darker. This black carbonised tissue was understood to be the slough and necrotic tissue having been solidified and lifted off the wound bed by the desiccant debridement process.

Afterwards, the treatment regimen continued to be the same as before. The devitalised tissue would be removed through the process of autolysis and sharp debridement at subsequent assessments by the district nursing to facilitate healing.

Follow-up

On the 4th day after application, Freddy developed sepsis and was hospitalised for 39 days. This was theorised to be a consequence of the cellulitis he had presented with, the result of microbes already present deep in the ulcer being able to spread throughout the body. During this period, his wound pain VAS score increased to 8/10, which was likely due to the infection changing from local to systemic in extent. As of the time of writing, this was his last occurrence of cellulitis.

For 1 month after discharge, Freddy's dressing regimen was changed to include silver foam, with the aim of managing biofilm production and exudate absorbency. His compression remained the same.

On 13 April 2022, 16 weeks after application, the wound was a similar size, measuring 15×20cm, but with no depth. It was still 100% covered in slough, but this was notable thinner and easier to remove with a curette. The exudate was moderate in level and less thick in consistency. The wound pain VAS score had reduced to 3/10.

It was evident that the wound had deteriorated further, and it was decided to apply Debrichem to it again. This

time, no topical anaesthetic was used, but again Freddy did not experience any pain during application. Afterwards, he began a new wound care treatment regimen, which comprised washing the wound in a bowl of warm water, cleansing it with irrigation solution for 10 minutes and using emollient to hydrate the skin. This was followed by mechanical debridement, dressing with antimicrobial silver Hydrofibre and compression therapy with 40mmHg toe-to-thigh inelastic compression bandaging, to increase the compression from above the knee.

On 11 May 2022, 4 weeks after the second application and 20 weeks after the first, the wound area was significantly smaller, measuring 11.1×11.8cm. The slough had become thinner and covered only 60% of the wound bed, with the other 40% showing healthy granulation tissue below the epidermis. The colour of the tissue had changed from yellow to green, suggesting local infection was reduced but still present. The exudate had reduced in level and had a thinner consistency and a more serous colour. Maceration continued to be a problem due to the size and chronicity of the ulceration and Freddy's lymphoedema in the thigh and habit of sleeping in his chair. Freddy did not report any pain.

Freddy's obesity, chronic lymphoedema and very large thigh area meant that wound healing could be improved by increased compression. This could be achieved with a compression wrap worn to the thigh, over the top of the short-stretch inelastic compression bandage worn from toe to thigh.

Discussion

In Freddy's case, the first application of Debrichem was followed by sepsis, hospitalisation and deterioration of the wound. However, the second application was followed by signs of wound healing, including epithelialisation of the wound bed and contraction of the wound edges. It would be valuable to explore the potential causes of these very different outcomes.

Another notable feature of Freddy's case was the absence of reported pain on application, with or without local anaesthetic. It would be very useful to understand what might have allowed Freddy to avoid the high temporary pain reported by other patients.

References

1. Wounds UK. Best practice statement: holistic management of venous leg ulceration. 2016. www.wounds-uk.com/resources/details/best-practice-statement-holistic-management-of-venous-leg-ulceration (accessed 21 February 2023)
2. Harper CD, Crane JS. Atrophie blanche. StatPearls. 2022. www.ncbi.nlm.nih.gov/books/NBK544285 (accessed 6 January 2022)
3. Hopkins A. How to apply effective multilayer compression bandaging. Wounds International. 2006; 1:28–42
4. Guest JF, Fuller GW, Vowden P. Cohort study evaluating the burden of wounds to the UK's National Health Service in 2017/2018: update from 2012/2013. *BMJ Open*. 2020;10(12):e045253. <https://doi.org/10.1136/bmjopen-2020-045253>

DEBRICHEM[®]

A new disruptive biofilm elimination method

DEBRICHEM is an acidic gel certified as a single-use medical device. The product is intended for topical application to an infected wound, to help facilitate removal of infection by the means of debridement, followed by cleaning and dressing.



**Removes biofilm
and infection**



Single application



**Easy to use in
60 seconds**

Get in touch

Barbara Strozzilaan 362
1083 HN – Amsterdam
info@debx-medical.com



www.debx-medical.com